

UNIVERSIDADE FEDERAL DO PARANÁ

LENARA GONÇALVES E SOUZA

COMPARATIVE INVESTIGATIONS OF TWO CATARACT-PREVENTING DRUGS
AND OF TWO DIFFERENT REBOUND TONOMETERS IN LABORATORY RATS

(Rattus norvegicus)

CURITIBA

2022

LENARA GONÇALVES E SOUZA

COMPARATIVE INVESTIGATIONS OF TWO CATARACT-PREVENTING DRUGS
AND OF TWO DIFFERENT REBOUND TONOMETERS IN LABORATORY RATS

(Rattus norvegicus)

Dissertação ao Curso de Pós-graduação em Ciências Veterinárias, Setor de Ciências Agrárias, Universidade Federal do Paraná, como requisito parcial a obtenção do título de mestre em Ciências Veterinárias.

Orientador: Prof. Fabiano Montiani-Ferreira
Coorientador: Prof. Alex Rafacho

CURITIBA

2022

DADOS INTERNACIONAIS DE CATALOGAÇÃO NA PUBLICAÇÃO (CIP)
UNIVERSIDADE FEDERAL DO PARANÁ
SISTEMA DE BIBLIOTECAS – BIBLIOTECA DE CIÊNCIAS AGRÁRIAS

Souza, Lenara Gonçalves e

Comparative investigations of two cataract-preventing drugs and of two different rebound tonometers in laboratory rats (*Rattus norvegicus*) / Lenara Gonçalves e Souza. – Curitiba, 2022.

1 recurso online: PDF.

Dissertação (Mestrado) – Universidade Federal do Paraná, Setor de Ciências Agrárias, Programa de Pós-Graduação em Ciências Veterinárias.

Orientador: Prof. Fabiano Montiani-Ferreira

Coorientador: Prof. Alex Rafacho

1. Ácido Lipoico. 2. Catarata. 3. Rato. I. Montiani-Ferreira, Fabiano. II. Rafacho, Alex. III. Universidade Federal do Paraná. Programa Pós-Graduação em Ciências Veterinárias. IV. Título.



MINISTÉRIO DA
EDUCAÇÃO SETOR DE
CIÊNCIAS AGRÁRIAS
UNIVERSIDADE FEDERAL DO PARANÁ
PRÓ-REITORIA DE PESQUISA E PÓS-
GRADUAÇÃO PROGRAMA DE PÓS-
GRADUAÇÃO CIÊNCIAS VETERINÁRIAS -
40001016023P3

TERMO DE APROVAÇÃO

Os membros da Banca Examinadora designada pelo Colegiado do Programa de Pós-Graduação CIÊNCIAS VETERINÁRIAS da Universidade Federal do Paraná foram convocados para realizar a arguição da dissertação de Mestrado de **LENARA GONÇALVES E SOUZA** intitulada: **Comparative investigations of two cataract-preventing drugs and of two different rebound tonometers in in laboratory rats (*Rattus norvegicus*)**, sob orientação do Prof. Dr. FABIANO MONTIANI FERREIRA, que após terem inquirido a aluna e realizada a avaliação do trabalho, são de parecer pela sua APROVAÇÃO no rito de defesa.

A outorga do título de mestra está sujeita à homologação pelo colegiado, ao atendimento de todas as indicações e correções solicitadas pela banca e ao pleno atendimento das demandas regimentais do Programa de Pós-Graduação.

CURITIBA, 01 de Junho de 2022.

Assinatura Eletrônica 06/06/2022

09:51:22.0

FABIANO MONTIANI FERREIRA

Presidente da Banca Examinadora

Assinatura Eletrônica 02/06/2022

13:37:44.0 ROGERIO RIBAS

LANGE

Avaliador Interno (UNIVERSIDADE FEDERAL DO PARANÁ)

Assinatura Eletrônica 02/06/2022

13:18:00.0

ANA LETICIA

GROSZEWICZ DE SOUZA

Avaliador Externo (QUALITTAS)

RUA DOS FUNCIONÁRIOS, 1540 - CURITIBA - Paraná - Brasil
CEP 80035050 - Tel: (41) 3350-5621 - E-mail: cpqcv@ufpr.br
Documento assinado eletronicamente de acordo com o disposto na legislação federal Decreto 8539 de 08 de outubro de 2015.

Gerado e autenticado pelo SIGA-UFPR, com a seguinte identificação única: 188907

Para autenticar este documento/assinatura, acesse
<https://www.prppq.ufpr.br/siga/visitante/autenticacaoassinaturas.jsp> e insira o código 188907

AGRADECIMENTOS

Quando me sentei para escrever estes agradecimentos, passou um filme na minha cabeça acerca dessa jornada. Cada momento e cada rosto, ou gesto. Começo agradecendo a vida e as oportunidades que Deus nos dá.

Me considero muito sortuda, e sou muito grata por ter a família que tenho. De pessoas que me colocam incrivelmente numa injeção de vontade pela vida, e me oportunizam e viabilizam tanta coisa. Minha família, minha base, minha rede de apoio, vocês foram essenciais para realização deste momento, meus pais (Vidal e Graça), meu irmão e sua família (Cristiano, Lelia, Lara e Pedro), meu filho (Augusto), minhas tias e primos. Agradeço ao meu filho, que é um presente em minha vida, minha inspiração diária. Agradeço minha prima e sua família (Mariana, Ronaldo, Júlia e Vinícius) pela acolhida em sua casa em Curitiba.

Agradeço ao meu orientador Fabiano Montiani Ferreira, a quem admiro e quem me inspira como profissional. Nossa história, já iniciada na época da residência, foi sempre de confiança e parceria. Agradeço a confiança em mim depositada, o apoio técnico científico, a compreensão, a amizade.

Agradeço aos meus amigos da pós-graduação, por todo apoio técnico, dando suporte de informações e inclusive apoio emocional. Especialmente aos amigos, Sabrine, Cláudia, Farah, Felipe, meu agradecimento e carinho.

Agradeço ao meu coorientador Professor Alex Rafacho, que sem nem me conhecer, aceitou ouvir minha proposta para co orientação e aceitou prontamente o convite, se colocando sempre presente e solícito, colocou o laboratório de sua supervisão à disposição. Auxiliou sem medir esforços, tanto na prática quanto na teoria. E a quem admiro muito também como profissional e como ser humano.

Agradeço aos amigos do LIDOC, Flávia, Rodrigo, Morgana, Priscila, Aline, Natália, Danilo, por todo o apoio na execução das pesquisas, pela paciência e tempo para ensinar desde o funcionamento do laboratório, até processamento de amostras. Além das companhias dos cafezinhos.

Agradeço aos colegas de profissão Laura e Lucas, pelo apoio com os pacientes e com equipamentos.

E aos tantos outros, que não foram nomeados, e que fizeram parte dessa caminhada.

RESUMO

O sentido da visão é essencial e muito importante para a maioria dos seres vivos. Ao longo dos anos, pesquisas são desenvolvidas ao redor do mundo, no intuito de prevenir e tratar doenças oculares, com recursos tecnológicos e farmacêuticos. Ao longo dessa dissertação se discutem alguns recursos importantes para diagnóstico e tratamento de doenças como glaucoma e complicações oculares de diabetes *mellitus*. A dissertação é composta de dois capítulos, sendo o primeiro intitulado “Comparative evaluation of two commercially available rebound tonometers in rats: TONO-VERA VET® and TD 8000®” e o segundo “A Comparative study of the use of topical lanosterol and na oral anti-oxidant vitamin complex to prevent diabetic cataracts in rats and in dogs”. No capítulo 1, comparou-se medidas de pressão intraocular em dois diferentes tonômetros Tono-Vera Vet® (TVV) e TD 8000® (TD8) em ratos. No capítulo 2, foi avaliada a progressão da opacidade da lente em ratos da raça Wistar induzidos, utilizando modelo experimental com estreptozotocina, ao diabetes *mellitus*, e de cães com diabetes *mellitus* natural, por meio de avaliação clínica oftalmológica durante tratamento com colírio contendo lanosterol ou complexo vitamínico contendo inibidor de aldose redutase (ácido alfa lipóico) baseado no medicamento disponível comercialmente Ocu-GLO®, com análise documentada e padronizada através de imagens fotográficas e análises complementares, tais como histopatologia (nos ratos). Os resultados obtidos trazem informações relevantes acerca de tonometria para diagnóstico glaucoma e tratamento preventivo para catarata diabética.

Palavras-chave: Tonometria, Estreptozotocina, Lanosterol, Ácido alfa lipóico, TONO-VERA VET® e TD 8000®

ABSTRACT

The sense of sight is essential and very important for most living beings. Over the years, innumerable scientific investigations has been developed around the world in order to prevent and treat a variety of eye diseases using, technological and pharmaceutical resources. Throughout this dissertation, important theories for the diagnosis and treatment of diseases such as glaucoma and ocular complications of diabetes *mellitus* are discussed. The dissertation consists of two chapters, the first entitled "Comparative evaluation of two commercially available rebound tonometers in rats: TONO-VERA VET® and TD 8000®" and the second "Use of Lanosterol eye drops and a compounded vision supplement based on OCU-GLO® to prevent diabetic cataracts in rats and in dogs - a comparative and effectiveness study". Chapter 1 compared intraocular pressure measurements in two different tonometers in rats, Tono-Vera Vet® (TVV) and TD 8000® (TD8) in rats. In chapter 2, the progression of lens opacity was evaluated in Wistar rats induced, using an experimental model with streptozotocin, to diabetes *mellitus*, and in dogs with natural diabetes *mellitus* was evaluated and compared, in animals treated with eye drops containing lanosterol or na orally administrated vitamin complex containing aldose reductase inhibitor (alpha lipoic acid), which was based on a commercially available drug Ocu-GLO®. A standardized analysis using photographic images was performed. With the conclusions of both studies, we bring results, with relevant information about tonometry for glaucoma diagnosis and preventive treatment for diabetic cataract.

Keywords: Tonometry, Streptozotocin, Lanosterol, Alpha Lipoic Acid, TONO-VERA VET® and TD 8000®

LIST OF ILLUSTRATIONS

Figure 1	Representative examples of IOP measurements using both rebound tonometers equipped with specially designed spacers that keep the eye probe distance at 6 mm TD8 (left) TVV (right).....	20
Figure 2	Representative examples of the spacer prototype made by the Software CAD Fusion 360, for both tonometers TD8 (left) and TVV (right).....	20
Figure 3	Box-plot graph of the results of a combined IOP mean (left and right), obtained with each rebound tonometer TD8 and TVV. Dots indicate outliers, which are less than 5% of the measurements.....	21
Figure 4	Bar graph of the rats evaluated in the right and left eye according to the groups for all timepoints. Note difference between the STZ groups and the control.....	38
Figure 5	Representative images of each grade of cataract evaluation via slit lamp grades in rats	38
Figure 6	Box plot graph representing weight in the diferente groups of rats.....	39
Figure 7	In the first image control group, and in the three subsequent images STZ groups. Showing lower body condition in the STZ groups.....	39
Figure 8	Blood glucose analyzed through 60 days.....	40

Figure 9	ALT, AST, and blood ketone bodies biochemical parameters analyzed	41
Figure 10	Histogram demonstrating the hepatic TG content in the different groups. Observe significant difference between STZ and CTL group , and between STZ-C and STZ.....	42
Figure 11	Histogram demonstrating body fat analisis. Epididymary fat analysis observe a significant difference between the CTL and STZ-L groups and between the CTL and STZ-C groups. Omental fat analysis was a significant difference between the CTL and STZ-C groups. Retropeirtoneal fat analysis was a significant difference between the groups.....	43
Figure 12	Histopathological analysis of the lens, on the left eye demonstrating that CTL and STZ-L groups are significantly different.....	44
Figure 13	Histopathological analysis of the lens, on the right eye demonstrating that CTL and STZ-L groups are significantly different...	44
Figure 14	Note grade zero, presence of anterior epithelium with lens fibers.....	45
Figure 15	Note grade one, presence of anterior epithelium, lens fibers and vacuoles.....	45
Figure 16	Note grade two, presence of anterior epithelium, lens fibers, vacuoles, and homogeneous area.....	46
Figure 17	Photomicrograph of a tissue of the pancreas of the control group on the left and on de right pancreas of the STZ group. Hematoxylin and eosin staining. Magnification 10X. Dimension of the islet was also considerably reduced and shrunken, on control group	46
Figure 18	IOP values was no significant difference was observed between groups and among time	47

Figure 19	Descriptive analysis of the degree of cataract of the dogs evaluated in the left eye in relation to all groups and time points. Note significant difference within the lanosterol group.....	48
Figure 20	Representative images of each grade of cataract evaluation via slit lamp grades in dogs	48
Figure 21	Boxplot of the dogs for the AH CA variable evaluated in the right and left eye in all trials and groups. Observe significant difference between anterior chamber (CA) measurements between the control and treated groups.....	49
Figure 22	Boxplot of the dogs for the AV CA variable evaluated in the right and left eye in all trials and groups. Observe significant difference between anterior chamber (CA) measurements between the control and treated groups.....	50

LIST OF TABLES

Table 1	Composition of the oral compound, received for the dogs. On the left for Dogs up to 5kg and on the right, between 5 and 15 kg.....	35
Table 2	Descriptive and inferential analysis of the degree of cataract of the dogs evaluated in the right and left eye in relation to all groups and time points. Observe mean between each group.....	47

SUMMARY

1.INTRODUCTION	15
2.CHAPTER 1 - COMPARATIVE EVALUATION OF TWO COMMERCIALY AVAILABLE REBOUND TONOMETERS IN RATS: TONO-VERA VET® AND TD 8000®	16
2.1 ABSTRACT	16
2.2. INTRODUCTION	17
2.3. MATERIALS AND METHODS	18
2.3.1. ANIMALS	18
2.3.2. EVALUATION OF TONOMETRY	19
2.3.3. STATISTICAL ANALYSIS	20
2.4. RESULTS	21
2.5. DISCUSSION	21
2.6. CONCLUSIONS	24
2.7. REFERENCES	24
3.CHAPTER 2 – A COMPARATIVE STUDY OF THE USE OF TOPICAL LANOSTEROL AND NA ORAL ANTI-OXIDANT VITAMIN COMPLEX TO PREVENT DIABETIC CATARACTS IN RATS AND IN DOGS	26

3.1. ABSTRACT	26
3.2. INTRODUCTION	28
3.3. MATERIALS AND METHODS	29
3.3.1. TREATMENT AND EVALUATION OF THE LANOSTEROL EYE DROPS AND VISION SUPPLEMENT IN RATS	30
3.3.1.1. STREPTOZOTOCIN MODEL	30
3.3.1.2. TREATMENT WITH LANOSTEROL EYE DROPS AND VISION SUPPLEMENT	31
3.3.1.3. EVALUATION OF IOP AND CATARACT VIA SLIT LAMP PHOTOGRAPHIC RECORDS	31
3.3.1.4. BODY WEIGHT AND GLYCEMIA ANALYSIS	32
3.3.1.5. SERUM BLOOD ANALYSIS AND BODY FAT ANALYSIS	32
3.3.1.6. HISTOPATHOLOGY ANALYSIS	33
3.3.2. TREATMENT AND EVALUATION OF THE LANOSTEROL EYE DROPS AND VISION SUPPLEMENT IN DOGS	33
3.3.2.1. INCLUSION CRITERIA	34

3.3.2.2. TREATMENT WITH LANOSTEROL EYE DROPS AND VISION SUPPLEMENT	34
3.3.2.3 CATARACT EVALUATION VIA SLIT LAMP PHOTOGRAPH RECORDS	36
3.3.2.4. OCULAR ULTRASONOGRAPHIC EVALUATION	37
3.3.3. STATISTICS ANALYSIS	37
3.4. RESULTS	37
3.4.1 RESULTS IN RATS	37
3.4.1.1. EVALUATION OF CATARACTS GRADES VIA SLIP LAMP	37
3.4.1.2. BODY WEIGHT AND BLOOD GLUCOSE IN RATS	39
3.4.1.3. ALT, AST, BLOOD KETONE BODIES, TG PLASMATIC, HEPATIC TG ANALYSIS	40
3.4.1.4. BODY FAT ANALYSIS (VISCERAL DEPOTS).....	42
3.4.1.5. LENS HISTOPATHOLOGY	43
3.4.1.6. HISTOPATHOLOGY OF PANCREAS	46
3.4.2. RESULTS IN DOGS	47

3.4.2.1. IOP MEASURE IN DOGS	47
3.4.2.2. EVALUATION OF CATARACTS GRADES VIA SLIT LAMP IN DOGS...	47
3.4.2.3. EVALUATION OF ULTRASONOGRAPHIC MEASURES	49
3.5.DISCUSSION	50
3.6. CONCLUSIONS	54
3.7.REFERENCES	54
4.FINAL CONSIDERATIONS.....	56
5. REFERENCES	57
APPENDIX.....	60

1. INTRODUCTION

Eye health is of paramount importance for the maintenance of vision. Therefore, a deeper understanding of eye diseases is necessary for maintaining good eye health. This paper consists of two chapters of experimental research. Both are related to eye pathologies, glaucoma and diabetic cataract respectively.

The objective of the first chapter was to compare intraocular pressure with two different tonometers, in rats. Since glaucoma is one of the eye diseases with great relevance that can lead to vision loss, an important equipment for the detection of intraocular pressure is the tonometer. This makes the accuracy of this measurement of relevance.

In the second chapter another experimental research is discussed, which is divided into two parts. This research investigates the effectiveness of two different medications for the prevention of diabetic cataracts and compares their actions. The main active ingredients of these medications are lanosterol and alpha lipoic acid. The first part of the research was carried out on rats and the second on dogs. As the line of the first chapter aimed to search for alternatives for diabetic cataracts, since this is also a relevant cause of vision loss in the world.

Regardless of the area of science, the role of research for humankind is one of growth and improvement in the quality of life of the world's population. This dissertation contributes to this scenario and to the development of science. Furthermore, the research was conducted ethically and with respect for the animals. Regarding the formatting of the document, the UFPR norms were followed.

2. CHAPTER 1 - COMPARATIVE EVALUATION OF TWO COMMERCIALLY AVAILABLE REBOUND TONOMETERS IN RATS: TONO-VERA VET® AND TD 8000®

2.1 ABSTRACT

Objective: The aim of this study was to compare intraocular pressure (IOP) measurements obtained using two different tonometers, Tono-Vera Vet® (TVV) and TD 8000® (TD8), once they are commonly used in veterinary practices.

Animal studied: IOP measurements were obtained in sixteen conscious Wistar rats, gently restrained by the examiners.

Procedures: A drop of tetracaine hydrochloride 1% were instilled on each eye. Measurements were taken sequentially, left eye first, then right eye with TD8, then with TVV tonometer. Distance from the cornea was kept constant by using a spacer measuring 6 mm in length. The tonometers probe was kept perpendicular to the eye. Both equipments automatically provided an average IOP through the respective software's algorithm.

Results: In our study, the mean values obtained using these tonometers were significantly different ($p=0,001$). Mean IOP obtained with TVV was significantly higher than with TD8, for TD8 the mean (+/- standard deviation) was 10.78 (+/- 1.13 and for TVV the mean (+/- standard deviation) was 17.12 (+/- 2,02).

Conclusion: Tono-Vera Vet® measurements were superior to those of the TD 8000®. Our hypothesis for this is the difference between software algorithms from both tonometers, once other factors for such differences were eliminated.

KEYWORDS: tonometry, rat, IOP, Tono-Vera Vet®, TD 8000®, eye.

2.2. INTRODUCTION

Glaucoma is a relevant cause of blindness in animals and humans. Without adequate treatment, glaucoma can progress to visual disability and eventual blindness. Intraocular pressure (IOP) is the only proven treatable risk factor (Weinreb *et al*, 2004).

Magrane, who first investigated the canine glaucomas in some detail during the 1950s wrote, “Glaucoma, whether it be in man or beast, is not in itself a disease entity. It, rather, consists of a ‘wastebasket’ group of diseases, which have as their common feature an abnormal elevation of intraocular pressure (IOP). This group may be referred to as the glaucomas” (Plummer *et al*, 2013). “The glaucomas” in fact are a group of optic neuropathies characterized by progressive degeneration of retinal ganglion cells. These central nervous system neurons have their cell bodies in the inner retina and axons in the optic nerve. Degeneration of these cells may result in retinal degeneration and optic disc cupping, a characteristic appearance of the optic disc and visual loss (Weinreb *et al*, 2004).

The three basic procedures for the diagnosis and clinical management of glaucomatous patients are tonometry, gonioscopy, and ophthalmoscopy (Plummer *et al*, 2013). Tonometry is the measurement of IOP and is an essential diagnostic procedure for a thorough ophthalmic examination (Featherstone *et al*, 2013). The ideal tonometer should be easy to use, atraumatic, require minimal restraint, and provide accurate and repeatable estimates of IOP in both normal and diseased eyes. Tonometers designed for use in Veterinary Medicine should be easy to use and carry but also accurate across a wide range of species with different ocular anatomy. Instrumental tonometry includes certain assumptions about various physical factors such as corneal thickness and curvature, corneal and scleral rigidity, tear film viscosity, and the effects of any topical medications that might be present (Featherstone *et al*, 2013).

Tonometers offer an indirect measurement of IOP, the method through which pressure is determined varies among instruments. Three main methods of measurement are applanation, indentation, and rebound (Stamper *et al*, 2011). Tono-Vera Vet® (TVV) (Reichert Instruments GmbH, Munich Germany) is a rebound tonometer for veterinary use only. TD 8000® (TD8) tonometer (Apramed Equipamentos Oftalmológicos-Brazil) is a rebound tonometer indicated for human use. Veterinary ophthalmologists in their practices also commonly use the latter.

Tonometry is difficult in rats and practically impossible in the mouse with applanation tonometers because of its sizeable footplate compared to the corneal diameter in these species.

The Tonovet or Tonolab (ICare- Helsinki, Finland), rebound tonometer, are much more appropriate for these species since its rebounding probe takes up less than 1mm of the corneal surface (Williams *et al*, 2012).

In fact, a precise and reliable instrument to measure IOP non-invasively is an important tool for the development and evaluation of different chronic glaucoma rat models. The I/I probe tonometer (ICare- Helsinki, Finland), the prototype for the modern Tonovet, was found to be reliable over the IOP range of 8.9–20.2 mmHg, with IOP measurements not significantly different from manometrically determined values. Thus, it is an acceptable method of determining even relatively small differences in IOP. Its design principle is potentially adaptable to non-invasive IOP determination in the smaller mouse eye, where the absolute pressures in different strains are within the range determined in study previously performed (Kontiola *et al*, 2001). In contrast, the error of the TonoPen increases below or above the IOP range of 9–20 mmHg and the measurements also have a greater variability. Therefore, the calibrated I/I probe tonometer offers a valid alternative to the commonly used TonoPen XL for accurate determination of IOP in the rat eye (Goldblum *et al*, 2002). Finally, the successful use of the I/I tonometer in Wistar rats indicates that the rebound tonometer method is useful for measuring IOP in small animal eyes and can potentially be scaled down to the mouse eye (Williams *et al*, 2012).

Currently, there are many tonometers commercially available, tonometers, which are considered as appropriate equipment for measuring IOP. In addition, many studies have compared different equipment to ensure accuracy. Both rebound tonometers tested in this study were poorly investigated previously, and were not compared accordingly to their measurements.

The purpose of this study is to evaluate potential differences between IOP measurements in rats, Tono-Vera Vet® and TD 8000®.

2.3. MATERIALS AND METHODS

2.3.1. ANIMALS

All procedures were approved by the Animal Use Committee of the Federal University of Santa Catarina (UFSC) and conducted in accordance with the ARVO Statement for the Use of Animals in Ophthalmic and Vision Research. Sixteen male Wistar rats with an average

weight of 350 g, were housed in an illuminated room that was turned on and off automatically every 12 hours (12-hour light/dark cycle); Four animals were housed per cage, at 22° C (more or less 2°C). Filtered tap water and rat chow pellets were available *ad libitum*.

2.3.2. EVALUATION OF TONOMETRY

Previous examination with a slit-lamp was performed to evaluate and check normal eye condition (Digital slit-lamp hyperion microclear 16 MPX, Optimetrics, Hialeah, FL, USA) also direct ophthalmoscopy examinations for anterior and posterior segment. A drop of tetracaine hydrochloride 1% were instilled on each eye. To obtain IOP measurements, examiners gently restrained the animals by holding the skin between its ears and tail, without putting pressure on the neck region. Measurements were taken in the morning, in a single moment, randomizing left (1) and right (2) eyes in Excel, using the formula RANDBETWEEN (1;2). Two rebound tonometers were used, TD 8 tonometer then TVV tonometer, making up two groups. Tono-Vera Vet® has a resource to selecting species for measure, and the chosen was 'rabbits'. Distance from the cornea for both tonometers was kept constant by using a 6 mm spacer specially designed for each instrument for this investigation (Figure 1). Prototype of the spacers was made by the Software CAD Fusion 360, which is illustrated in figure 2. The positioning angle from the cornea was approximately 15 degrees, with the probe perpendicular to the eye, on the central area of cornea. Measurements were taken from each eye randomly and with each equipment, all at the same moment. Three measurements were taken with TD8 and then equipment automatically provided an average, through the software's algorithm. Auto system mode of Tono-Vera Vet® was chosen, this way the device automatically measured when properly aligned. The Tono-Vera Vet® count with upgrades to improve, accuracy has species-specific settings for rabbits, brings features that ensure readings are only obtained when the tonometer is in appropriate distance and correct position to the ocular surface. Measurements were taken until a high-confidence IOP result was obtained, a minimum of three measurements and a maximum of six.

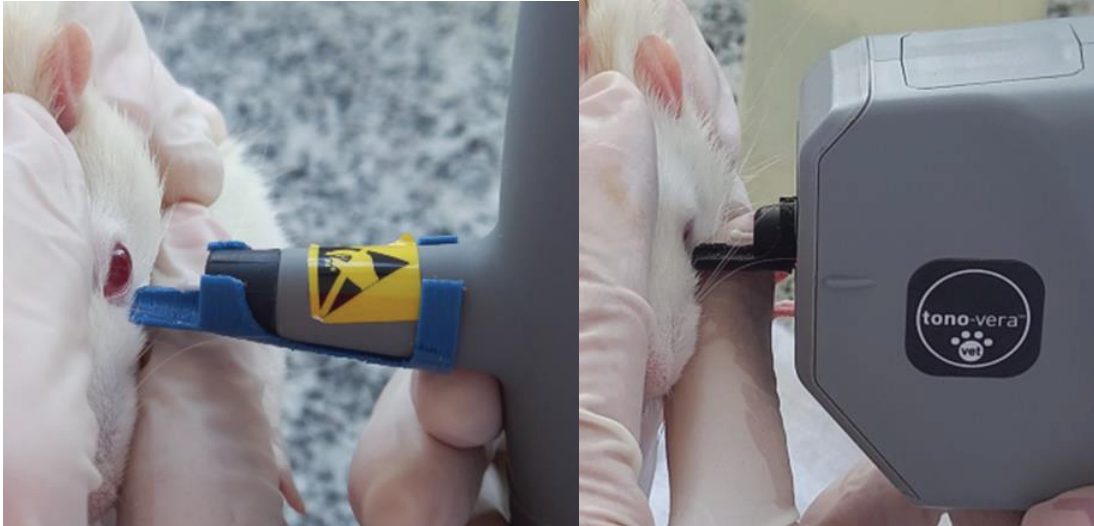

Figure 1. Representative examples of IOP measurements using both rebound tonometers equipped with specially designed spacers that keep the eye probe distance at 6 mm TD8 (left) TVV (right).



Figure 2. Representative examples of the spacer prototype made by the Software CAD Fusion 360, for both tonometers TD8 (left) and TVV (right).

2.3.3. STATISTICAL ANALYSIS

Statistical analyses were performed using two different statistical software packages (Excel [Redmond, WA] and GraphPad Prism [GraphPad Software]). Mean and standard deviation were calculated from the sixteen animals, from each right and left eye. Data from the left and right eye were compared from both tonometers, Bland altman test was performed between right and left eye to both tonometers. For TVV bias was -6.94, for 95% degrees of agreement from -35.12 to 21.23 and For TD8 bias zero for 95% degrees of agreement from -2.37 to 2.37, which means that eye side has no influence on the final results. Data were normally distributed according to Anderson-Darling test. Na IOP average of the right and left eyes were then analyzed using paired Student's t-test..

2.4. RESULTS

TD8 the IOP mean (+/- standard deviation) was 10.78 +/- 1.13 and TVV was 17.12 +/- 2.02. Mean IOP obtained with TVV was significantly higher than with TD8 ($p=0,001$). Graph 1 shows a summary of the IOP data obtained with each tonometer, including central tendency, dispersion and minimum and maximum values. Represented in Figure 3.

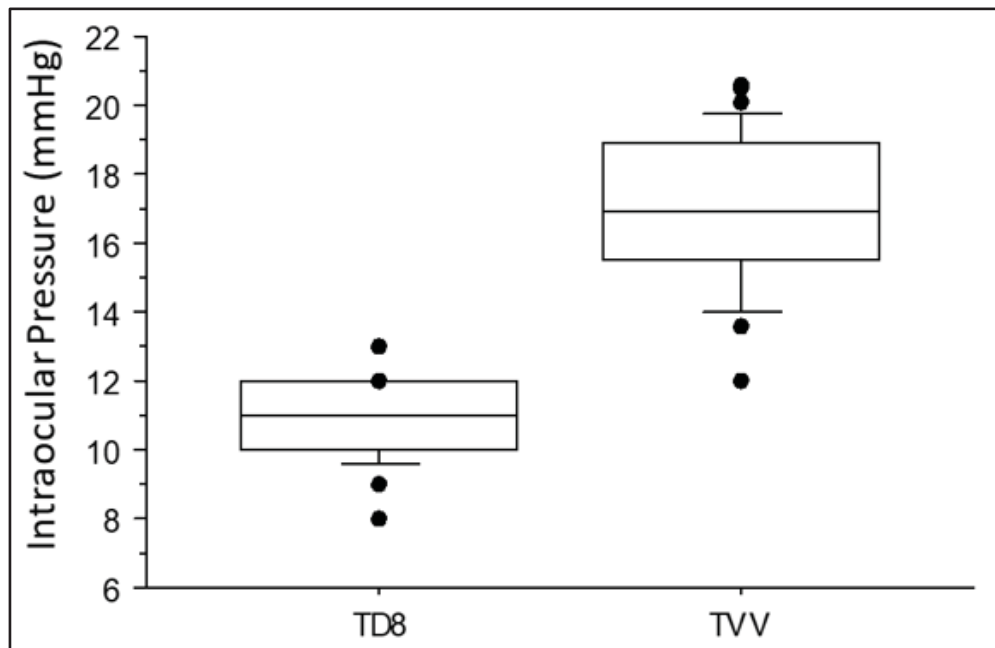


Figure 3. Box-plot graph of the results of a combined IOP mean (left and right), obtained with each rebound tonometer TD8 and TVV. Dots indicate outliers, which are less than 5% of the measurements.

2.5. DISCUSSION

Direct tonometry via a manometer is the most direct and accurate method available for IOP acquisition but is particularly invasive and therefore impractical for clinical use. Indirect tonometry, the measurement of corneal tension, is the technique used to determine IOP in clinical ophthalmology. It is a quick, simple, noninvasive procedure that can be performed with minimal discomfort to the patient, and the results determine not only the diagnosis but also the prognosis and treatment option. Multiple factors can influence tonometric readings. Some factors are inherent to the type of tonometer (size of probe on a cornea with extensive pathology) and to the angle, whereas others are beyond the control of the examiner (age, gender, season). Adjunctive methods are required for reliable tonometry and can affect the IOP results. These include sedation, general anesthesia, and regional nerve blocks. The method

of restraint (physical and chemical) and body and head position can also have a dramatic effect (Stamper, 2011).

Behavioral training of mice could avoid the use of a restraining device for awake IOP measurement, concluding that the behavioral training of mice could provide an approach that not only measures conscious IOP with reliability (Ding *et al*, 2011). Mice were familiar with restraint, so we assume this fact will not interfere in IOP measurement. Besides, both groups were under the same manipulation. Still, restraint mimics real clinical situations of how IOP will be measured.

Kontiola *et al*, cited by RODRIGUES *et al* (2020), showed in Wistar rats that IOP measurements were relatively unaffected by the initial distance of the probe from the cornea within 3-5 mm. A possible explanation for this is that in all of these previous investigations only relatively small distances (from 3 to 5 mm) from the probe to the corneal surface were tested. In order to find significant differences in IOP, a longer distance and a set of distances with larger differences were probably needed. In a previous investigation, greater distances (4, 6, and 8 mm) were compared, and with greater probe-cornea distances, the observed differences in IOPs became larger (Rodrigues *et al*, 2021). The Range of tonometers tested here were between 4 to 9 mm distances. Indeed based on the results presented in study by RODRIGUES, *et al* (2020) showed that there is a small, yet significant, positive correlation between the distance of the TonoVet® probe from the corneal surface and IOP value, even within the range of distances designated by the manufacturer. Therefore, in clinical conditions these suggestions might be somewhat impractical due to small movements normally caused by conscious animals and/or the examiner, they suggests reporting the distance at which the rebound tonometer's probe was kept from the corneal surface, especially in research settings throughout the entire investigation, in order to ensure repeatability of the IOP measurements when using rebound tonometry. Their recommendation would be to control the probe-cornea distance variable (ie, by using spacers as those used in this experiment or other devices), whenever IOP readings are obtained for research purposes (Rodrigues *et al*, 2021). To avoid this influence we used a spacer measuring 6 mm, standardizing the distance. We have developed two spacers, one for each tonometer, which can be used as an accessory.

Because of the small corneal surface, any lateral movement in the clamp/tonometer could have affected the readings in the rats. Nevertheless, a proportion of outliers of <5% was considered low, similarly to what was obtained by Rodrigues *et al*, (2021) .

One study compared intraocular pressure obtained by the portable rebound tonometers Tonovet® (ICare- Helsinki, Finland) and TD 8000® (Apramed Ophthalmic Equipments - Brazil) in dogs (Sereno *et al*, 2021). In this study, IOP obtained with both tonometers were concordant but there were significantly different comparing the two measuring devices. Although concordant within normotensive eyes measurements IOP values obtained with Tonovet® were higher than those obtained with TD8. In our findings IOP values obtained with TD8, although concordant within normotensive eyes in rats also were significantly lower than IOP values obtained with another rebound tonometer. In our study, however, TVV was used instead of Tonovet® for comparison.

Another tonometer, TONOVET Plus, not yet compared thus far to the authors' knowledge, has a similar mechanism to obtain IOP measure. The TONOVET Plus contains upgrades meant to improve accuracy and ease of use. The TONOVET Plus has species-specific settings for both rabbits ('lapine') and cats ('feline'), in addition to dogs and horses. Furthermore, features have been added that ensure readings are only obtained when the tonometer is held an appropriate distance and in the correct plane relative to the ocular surface. Messages indicating "too near" or "too far" appear on the screen when the device is not positioned at the correct distance and a ring surrounding the probe will change from green to red when it is not in the correct plane. In both cases, measurements cannot be taken until the distance or orientation issue has been corrected (Gloe *et al*, 2019). We suggest comparing the TONOVET Plus with tonometers we have tested here. In addition, mainly to validate IOP for rats, more studies are necessary, including manometric pressure. Both of these were limitations of our study. Although according to TVV brochure, the equipment's accuracy was checked by manometric measurements and fall within a 95% confidence interval.

Furthermore, previous study observed that the fact IOP values obtained with the TD8 tonometer, were lower compared with TVV, is an important clinical observation, relevant for glaucoma diagnosis. In one study, Tonovet® also underestimated the intraocular pressure in rats (Rocha-Sousa *et al*, 2014). On the other hand, while slightly more accurate, values obtained with the Tono-Pen VET displayed greater variance than those obtained with the TonoVet (Snyder *et al*, 2018). Similarly, the Tono-Pen Avia recorded higher levels of IOP compared with Tonovet, and showed higher variation between individuals (Pereira *et al*, 2011). Also, in a study with dogs, although all tonometers underestimated IOP (compared with manometry), particularly at higher IOPs, the degree of underestimation was much less with the ICare®

TONOVET Plus, whereas this underestimation was more pronounced with applanation tonometers (Tono-Pen Vet™ and Tono-Pen AVIA Vet™) (Minella *et al*, 2014).

Furthermore, several authors have found closer values using of Tonolab to manometric pressure than using Tonopen in rats (Ohashi *et al*, 2014, Pease *et al*, 2006, Wang *et al* 2013),, which leads to the conclusion that rebound tonometers are very appropriate for this species.

2.6. CONCLUSIONS

This is the first study to show differences in IOP when using Tono-Vera Vet® tonometer and Digital tonometer TD 8000® in rats. In our study, mean obtained with these two tonometers, which differs significantly. Tono-Vera Vet® IOP values underestimates those obtained with TD 8000®.

Also, we suggest comparing the TONOVET Plus with tonometers we have tested here. In addition, mainly to validate IOP for rats, more studies are necessary, including manometric pressure. Both of these were limitations of our study.

2.7. REFERENCES

- Ding, C., Wang, P., & Tian, N. (2011). Effect of general anesthetics on IOP in elevated IOP mouse model. *Experimental Eye Research*, 92(6), 512–520.
- Featherstone, H. J. and Heinrich, C. L. (2013). Ophthalmic Examination and Diagnostics Part 1: The Eye Examination and Diagnostic Procedures. In: *Veterinary Ophthalmology*. Kirk N. Gelatt. Wiley Blackwell, 1(10), 583-590.
- Goldblum, D., Kontiola, A. I., Mittag, T., Chen, B., & Danias, J. (2002). Non-invasive determination of intraocular pressure in the rat eye. Comparison of an electronic tonometer (TonoPen), and a rebound (impact probe) tonometer. *Graefe's Archive for Clinical and Experimental Ophthalmology*, 240 (11), 942–946.
- Gloe, S., Rothering, A., Kiland, J. A., & McLellan, G. J. (2019). Validation of the Icare® TONOVET plus rebound tonometer in normal rabbit eyes. *Experimental Eye Research*, 185.
- Kontiola, A. I., Goldblum, D., Mittag, T., & Danias, J. (2001). The induction/impact tonometer: A new instrument to measure intraocular pressure in the rat. *Experimental Eye Research*, 73(6), 781–785.
- Minella, A. L., Kiland, J. A., Gloe, S., & McLellan, G. J. (2021). Validation and comparison of four handheld tonometers in normal ex vivo canine eyes. *Veterinary Ophthalmology*, 24(S1), 162–170.

- Ohashi, M., Aihara, M., Saeki, T., & Araie, M. (2008). Efficacy of TonoLab in detecting physiological and pharmacological changes in rat intraocular pressure: Comparison of TonoPen and microneedle manometry. *Japanese Journal of Ophthalmology*, 52(5), 399–403.
- Pease, M. E., Hammond, J. C., & Quigley, H. A. (2006). *Manometric Calibration and Comparison of TonoLab and TonoPen Tonometers in Rats With Experimental Glaucoma and in Normal Mice*. 15 (6), 512-519.
- Pereira, F. Q., Bercht, B. S., Soares, M. G., da Mota, M. G. B., & Pigatto, J. A. T. (2011). Comparison of a rebound and an applanation tonometer for measuring intraocular pressure in normal rabbits. *Veterinary Ophthalmology*, 14(5), 321–326.
- Plummer, C. E., Reignier, A., Gelatt, K. N. The Canine Glaucomas. In: *Veterinary Ophthalmology*. Wiley-Blackwell, 2 (19), 1050.
- Rocha-Sousa, A., Pereira-Silva, P., Tavares-Silva, M., Azevedo-Pinto, S., Rodrigues-Araújo, J., Pinho, S., Avelino, A., Falcão-Reis, F., & Leite-Moreira, A. (2014). Identification of the ghrelin-GHSR 1 system and its influence in the modulation of induced ocular hypertension in rabbit and rat eyes. *Peptides*, 57, 59–66.
- Rodrigues, B. D., Montiani-Ferreira, F., Bortolini, M., Somma, A. T., Komáromy, A. M., & Dornbusch, P. T. (2021). Intraocular pressure measurements using the TONOVET® rebound tonometer: Influence of the probe-cornea distance. *Veterinary Ophthalmology*, 24(S1), 175–185.
- Sereno, M. G.; Cremonini, D. N.; Chiurchiu, J. L. V. (2021) Comparison Between Rebound Tonometer Tonovet ® and TD8000® in normotensive dogs. In: *Archives of Veterinary Science*, XVII CBOV, 26, (4), 15-97.
- Snyder, K. C., Lewin, A. C., Mans, C., & McLellan, G. J. (2018). Tonometer validation and intraocular pressure reference values in the normal chinchilla (*Chinchilla lanigera*). *Veterinary Ophthalmology*, 21(1), 4–9.
- Stamper, R.L. History of intraocular pressure and its measurement. *Optom Vis Sci*. 2011;88(1):E16-E28.
- Wang, X., Dong, J., & Wu, Q. (2013). Twenty-four-hour measurement of IOP in rabbits using rebound tonometer. *Veterinary Ophthalmology*, 16(6), 423–428.
- Weinreb, R.N.; Khaw, P. T. (2004). Primary open-angle glaucoma. *Lancet*.;363(9422):1711-1720.
- Williams, D. L. (2012). Common features of exotic animal ophthalmology. In: *Ophthalmology of exotic pets*. Wiley-Blackwell, 2 (7), 86-106.

3. CHAPTER 2 – A COMPARATIVE STUDY OF THE USE OF TOPICAL LANOSTEROL AND AN ORAL ANTI-OXIDANT VITAMIN COMPLEX TO PREVENT DIABETIC CATARACTS IN RATS AND IN DOGS

3.1. ABSTRACT

Objective: The aim of this study was to analyze and compare the response of preventive treatment of diabetic cataract development using a lanosterol-containing eye drops vs an oral anti-oxidant vitamin complex.

Animal studied: This study was divided into two parts: in the first part of the study, 37 male, Wistar rats were evaluated at the end of the study. In the second part of the study, eight dogs, male, of different breeds, presenting diabetes mellitus up to 6 months, treated with insulin, without other associated diseases, without other ocular alterations, were evaluated at the end of the study.

Procedures: Rats were randomly divided into 4 groups: control (non-diabetic) and the other three had streptozotocin induction and were divided into 3 groups; these are streptozotocin (STZ), streptozotocin treated with lanosterol eye drops (STZ L) and streptozotocin treated with oral anti-oxidant vitamin complex (STZ C). They were treated for 60 days. During this period, there were four evaluation times. The following evaluations were made: clinical evaluation in the slit lamp body weight, blood glucose, ALT, AST, ketone bodies, triglycerides, liver TG, plasma TG, histopathology of liver, pancreas and eyes and body fat. Dogs were randomly divided into 3 groups controlled diabetics, diabetics treated with lanosterol eye drops and diabetics treated with anti-oxidant vitamin complex via oral, for 60 days. The following assessments were made: Clinical, ultrasonographic and histopathological evaluation.

Results: In rats, there was no significant difference between STZ groups considering cataract evaluation via slit lamp. However, there was a difference between the STZ groups and the control ($p = 0.015$) for left eye, and ($p=0.019$) for right eye. There was a significant difference in body weight between control and STZ groups, $p < 0.0001$. ALT, AST, ketone bodies, plasma TG analysis there were not significantly different between groups. TG hepatic analysis, there were significant differences between STZ and CTL group ($p = 0,0002$) , between STZ and CTL-L ($p = 0.004$) and between STZ-C and STZ ($p = 0.037$). In the histopathological analyses of the lens, there was a significant difference between the CTL and STZ-L groups ($p = 0.007$). Epididymary fat was a significantly different between the CTL and STZ-L groups and between the CTL and STZ-C groups ($p= 0.004$), in the omental fat analysis there was a significant difference between the CTL and STZ-C groups ($p = 0.0002$), in the retroperitoneal fat analysis there was a significant difference between the groups, ($p=0.02$). In dogs, cataract evaluation via slit lamp showed a significant difference in the lanosterol group ($p=0.039$). Also in dogs, there was a significant difference between anterior chamber (CA) measurements between the control and treated groups, $p=0.036$ on the right eye and $p=0.002$ on the left eye.

Conclusion: There was no previous comparative study of these two drugs, and only a few studies with lanosterol. In addition, the present experimental procedure was regarded as a good model to induce diabetic cataract in rats. Concerning dogs, we suggest studies with larger samples. In our findings, neither lanosterol eye drops or anti-oxidant vitamin complex containing aldose reductase inhibitor (alpha lipoic acid) obtained preventive action for diabetic cataracts, not reducing the opacity of the lens in rats and dogs. Still, the anti-oxidant vitamin complex improved the changes in lipid metabolism and liver function caused by streptozotocin.

Key Words: Lanosterol, eye drops, alpha lipoic acid, streptozotocin, rats, dogs.

3.2. INTRODUCTION

Diabetes mellitus is commonly associated with rapidly developing, bilaterally symmetric cataract formation, from well-characterized alterations in lens metabolic pathways. With elevated blood glucose levels, lens levels of glucose increase, and anaerobic metabolism of glucose by the hexokinase pathways becomes saturated, causing shunting toward an alternate energy pathway involving the enzyme aldose reductase (AR). AR activity in diabetic cataracts is increased due to increased amounts of AR rather than increased enzyme activation. By utilizing nicotinamide-adenine dinucleotide phosphate (NADPH), AR reduces the aldehyde form of glucose to sorbitol, which is further oxidized to fructose by NAD-dependent sorbitol dehydrogenase. Accumulation of sorbitol (a polyol or sugar alcohol) results, which does not readily diffuse across the lens capsule. Water from the aqueous humor is imbibed into the lens due to osmotic forces, causing lens architectural changes, including fiber swelling and rupture, vacuole formation, and clinically evident cataract (Davidson *et al.*, 2013).

Streptozotocin (STZ), an antibiotic produced by *Streptomyces achromogenes*, is the most commonly used agent in experimental diabetes. The mechanism by which STZ destroys β -cells of the pancreas and induces hyperglycemia is still unclear. Many actions have been attributed to STZ that are similar to those that have been described for the diabetogenic action of alloxan, including damage to pancreatic β -cell membranes and depletion of intracellular nicotinamide adenine dinucleotide (NAD) in islet cells (Alimohammadi *et al.*, 2013).

Lanosterol plays a key role in inhibiting lens protein aggregation and reducing cataract formation, suggesting a novel strategy for the prevention and treatment of cataracts. Cataracts are the leading cause of blindness and millions of patients every year undergo cataract surgery to remove the opacified lenses. The surgery, although very successful, is nonetheless associated with complications and morbidities. Therefore, pharmacological treatment to reverse cataracts could have large health and economic impacts (Zhao *et al.*, 2015).

Light-scattering measurements indicated that dietary α -Lipoic acid is effective in delaying not only cataract development but also its progression. α -Lipoic acid may be able to do this by preventing protein glycation and reducing oxidative stress, two of the three putative mechanisms of diabetic cataractogenesis; α -Lipoic acid is ineffective in reducing polyol pathway activity, the third mechanism (Kojima *et al*; 2007).

The purpose of this study was to evaluate the progression of lens opacity in Wistar rats induced, using an experimental model with streptozotocin, to *diabetes mellitus*, through clinical ophthalmologic evaluation during treatment with eye drops containing lanosterol or anti-oxidant vitamin complex containing aldose reductase inhibitor (alpha lipoic acid), with documented and standardized analysis through photographic images and histopathological analysis at the end of treatment, also to evaluate the progression of lens opacity in dogs, with *diabetes mellitus*, through clinical ophthalmologic evaluation during treatment with eye drops containing lanosterol or medication containing aldose reductase inhibitor and antioxidants, with documented and standardized analysis through photographic images and ultrasonographic analysis.

3.3. MATERIALS AND METHODS

All procedures were approved by the Animal Use Committee (034/2021) of the Federal University of Parana (UFPR) Federal University of Santa Catarina (UFSC) Committee for Ethics in Animal Experimentation (PP00782) in accordance with the Brazilian National Council for Animal Experimentation Control (CONCEA) and the National Institutes of Health guide for the care and use of laboratory animals (NIH Publications No. 8023, revised 1978). This investigation was performed in two parts: evaluation of the lanosterol eye drops and vision supplement in rats and in dogs.

3.3.1. TREATMENT AND EVALUATION OF THE LANOSTEROL EYE DROPS AND VISION SUPPLEMENT IN RATS

3.3.1.1. STREPTOZOTOCIN MODEL

Subject for the first part of this study were fifty male Wistar rats (*rattus norvegicus*), around 200g. They had species-specific food and water intake *ad libitum*, submitted for 10 days of adaptation. They had an environment with a 12-hour light cycle (light on at 06:00) or (day/night), with a temperature of 22°C (plus or minus 2°C). The animals were divided into 4 animals, per cage. STZ (Sigma-Aldrich) was dissolved in 0.01 M buffered sodium citrate (Sigma-Aldrich), pH of 4.5. Of the 50 animals, 42 were induced with streptozotocin (STZ) single-dose intraperitoneal application of 66 mg/kg and 8 with a volume of 2 ml/kg of buffered sodium citrate intraperitoneal application, which were control (CTL). Blood glucose was measured 48 hours after induction (T0), using a glucometer (Accu check performa). This measurement was done under conditions of minimal stress to the animals, through a puncture in the tail vein. Of these, 6 animals were normal glycemically after 24 hours and were excluded from the study. Of the remaining diabetic rats, were randomized and distributed in 3 groups randomly distributed, untreated STZ induction, STZ induction treated with lanosterol eye drops (STZ-L) and STZ induction treated with anti-oxidant vitamin complex (STZ-C). To ensure that they were diabetic throughout the experiment (maintenance of baseline blood glucose values greater than or equal to 200 mg/dL) blood glucose measurements were performed weekly until the end of the experiment, which lasted 8 weeks. Water with 10% sucrose was used in the first 48 hours after the induction in order to reduce the blood glucose levels in order to reduce mortality due to hypoglycemia.

3.3.1.2. TREATMENT WITH LANOSTEROL EYE DROPS AND VISION SUPPLEMENT

From the moment the diagnosis of *diabetes mellitus* (baseline glucose greater than 200 mg/dL), the application of the eye drops or oral medication began. The eye drops containing lanosterol 0,5% were applied, one drop, in each eye, every 12 hours, until the animals were euthanized, in 60 days. The oral medication was administered in a dose corresponding to the animal's body mass, every 24 hours (equivalent to 1 mL/kg of body mass), until the animals were euthanized, in 60 days. The dose of the oral anti-oxidant vitamin complex were based on alpha lipoic acid, and were 30 mg/animal per day, similar to the study by Kojima *et al*; (2007). The drug that were administered orally, had its formulation in suspension using gavage. In the control group and in the STZ group, placebo was used.

3.3.1.3. EVALUATION OF IOP AND CATARACT VIA SLIT LAMP PHOTOGRAPHIC RECORDS

Evaluation were performed in four times (range of 4 weeks each). T0 (48 hour after STZ induction), T1 (20 days after T0), T2 (40 days after T0), T3 (60 days after T0). Ophthalmic examination of pupillary reflex, menace response, dazzle reflex, evaluation of eye segments with digital slit-lamp (Hyperion microclear 16 MPX, Optimetrics, Hialeah, FL, USA), (taking photographic records), intraocular pressure (IOP) (Tono-Vera Vet® Reichert Instruments GmbH, Munich Germany) were performed. Data of slit lamp photographic records were collected and analyzed. The severity of the cataract were graded according to the method performed by Thiraphatthanavong *et al*, (2014), and described below:

- Grade 0. Transparent lenses without vacuoles.

- Grade 1. Vacuoles covering approximately half the surface of the anterior pole forming subcapsular cataract.
- Grade 2. Some vacuoles have disappeared and the cortex exhibits an opacity.
- Grade 3. Opaque cortex remains and dense nuclear opacity is present.
- Grade 4. A mature cataract is observed as dense opacity in both the cortex and in the nucleus.

3.3.1.4. BODY WEIGHT AND GLYCEMIA ANALYSIS

The body weight was measured weekly, in a digital electronic scale (TECNAL, Piracicaba, SP, Brazil), thus obtaining thirteen weight measurements over the 60 days.

In addition, to ensure the diabetic state, throughout the time, eight blood glucose measurements were taken. The blood sample was collected from the tail vein and the blood glucose measured in a glucometer (Accu-Chek Performa; Roche Diagnostics, GmbH, Mannheim, Germany)

Body mass and blood glucose data were analyzed.

3.3.1.5. SERUM BLOOD ANALYSIS AND BODY FAT ANALYSIS

The euthanasia occurred in the end of 60 days and was done by exposure to halothane, followed by decapitation. Organs of interest (liver, pancreas, eye) were carefully removed and body fat depots weighed on an electronic analytical balance. Fragments of pancreas and liver were used for histological procedures as described in detail thereafter. The blood from the trunk was collected in a glass tube containing EDTA-NaF (Glistab, Labtest, Lagoa Santa, MG, Brazil) and then centrifuged at 1,500 rpm for 10 min at room temperature (Eppendorf 5810R). Aliquots of plasma stored at $-20\text{ }^{\circ}\text{C}$ for further quantification of plasmatic triacylglycerol

(plasmatic TG), ALT and AST (commercial kits from Biotécnica, Varginha, MG, Brazil) according to manufacturer's instructions. Sample was also collected for dosage of hepatic triglyceride concentration (TG). Blood ketone bodies were measured using the equipment Free Style (Abott - Free Style libre).

3.3.1.6. HISTOPATHOLOGY ANALYSIS

For hepatic, pancreatic and eye morphology, tissue fragments were collected and fixed in 10% buffered formalin, pH 7.4, for 24 h, dehydrated and embedded in paraffin. Representative tissue sections 5 µm for liver and pancreas and 4 µm for the eye, were obtained on a rotating microtome (Leica, IL, USA) and placed on glass slides. After, the slides were submitted to the staining procedure of Hematoxylin and Eosin (HE) for posterior morphological evaluation and grade classification of the lens in eyes.

The severity of histomorphological change of the lens will be given according to the method performed by Thiraphatthanavong, P. et al, (2014), and described below:

Grade 0. Presence of anterior epithelium with lens fibers.

Grade 1. Presence of anterior epithelium, lens fibers, and vacuoles.

Grade 2. Presence of anterior epithelium, lens fibers, vacuoles, and homogeneous area.

Grade 3. Absence of anterior epithelium, presence of lens fibers, vacuoles and homogeneous

homogeneous area.

Grade 4. Presence of lens fibers and homogeneous area only.

3.3.2. TREATMENT AND EVALUATION OF THE LANOSTEROL EYE DROPS AND VISION SUPPLEMENT IN DOGS

3.3.2.1. INCLUSION CRITERIA

The inclusion criteria for the dogs were animals up to 6 months diagnosed with *diabetes mellitus*, using insulin (caninsulin), and under recommendations and clinical management made under the guidance of a single professional, specialized in endocrinology. The animals were of different breeds and ages, no other concomitant diseases or concomitant ophthalmic abnormalities.

3.3.2.2. TREATMENT WITH LANOSTEROL EYE DROPS AND VISION SUPPLEMENT

From the moment the diagnosis, and beginning treatment of *diabetes mellitus* (baseline glucose greater than 200 mg/dL), patients underwent thorough ophthalmic examination, performing menace response test, pupillary light reflex, dazzle reflex, Schirmer tear evaluation test, evaluation of eye segments with digital slit-lamp (Hyperion microclear 16 MPX, Optimetrics, Hialeah, FL, USA), (taking photographic records) , intraocular pressure (IOP) (Tono-Vera Vet® Reichert Instruments GmbH, Munich Germany), indirect ophthalmoscopy were evaluated. Also, ocular ultrasound evaluation was performed. Then, the application of the eye drops or oral medication began. Eye drops containing lanosterol at a concentration of 0.5% were applied, one drop, in each eye, every 12 hours, for 60 days. The anti-oxidant vitamin complex medication were administered in a dose corresponding to the animal's body mass, every 24 hours, for 60 days. The medication were administered orally, with a palatable flavor. The following table 1, was the composition of the oral compound.

	Dogs up to 5kg	Dogs between 5 - 15kg
Lutein	1 mg	2 mg
Alpha Lipoic Acid	13 mg	25 mg
Folic Acid	20 mcg	40 mcg
Pantothenic Acid	1 mg	2 mg
Biotin	10 mcg	20 mcg
Green Tea Dry Extract	20 mg	40 mg
Coenzyme Q10	13 mg	25 mg
FC pet*	25 mg	50 mg
Lycopene	1 mg	2 mg
Rutin	5 mg	10 mg
Vitamin B1	0,1 mg	0,2 mg
Vitamin B3	1,2 mg	2,4 mg
Vitamin B6	0,1 mg	0,2 mg
Vitamin B12	2,5 mcg	5 mcg

Vitamin C	50 mg	100 mg
Vitamin E	25 UI	50 UI
Zinc	3 mg	5 mg
Vehicle qsp	1 dose	1 dose

*Phospholipids from caviar, rich in PUFAs (polyunsaturated fatty acids), omega-3 (DHA and EPA), vitamin E, and astaxanthin

Table 1. Composition of the oral compound, received for the dogs. On the left for Dogs up to 5kg and on the right, between 5 and 15 kg.

3.3.2.3 CATARACT EVALUATION VIA SLIT LAMP PHOTOGRAPH RECORDS

Cataract Evaluation via slit lamp photographic data were collected and analyzed. These analysis were performed in four times: T0 (from the moment the diagnosis, and beginning treatment of *diabetes mellitus*), T1 (30 days after T0), T2 (60 days after T0). The severity of the cataract were graded based on the method performed by Thiraphatthanavong *et al*, (2014), and described below:

- Grade 0. Transparent lenses without vacuoles.
- Grade 1. Vacuoles covering approximately half the surface of the anterior pole forming subcapsular cataract.
- Grade 2. Some vacuoles have disappeared and the cortex exhibits an opacity.
- Grade 3. Opaque cortex remains and dense nuclear opacity is present.
- Grade 4. A mature cataract is observed as dense opacity in both the cortex and in the nucleus.

For dogs, for a more precise description of the lesion, we included one more grade:

- Grade 5. Reabsortive (morganian) cataract

3.3.2.4. OCULAR ULTRASONOGRAPHIC EVALUATION

Based on the protocol performed by Williams (2004), axial globe length measurements were determined both horizontally and vertically, as well as lens thickness and anterior chamber depth. Data were obtained as the average of the distances of three ultrasounds for each measurement. Ultrasounds were rejected when the measured distances were more than 5% different from others from the same eye.

3.3.3. STATISTICS ANALYSIS

Descriptive statistics were calculated and presented for each group. For those which had normal distribution, ANOVA (when more than 3 groups were compared) Student T-test (when 2 groups were compared) were performed, and for those without normal distribution, Kruskal-Wallis test was performed. $P < 0.05$ considered.

3.4. RESULTS

3.4.1. RESULTS IN RATS

3.4.1.1. EVALUATION OF CATARACTS GRADES VIA SLIT LAMP

Data were analyzed across time and between groups, and there was no significant difference between STZ groups or times. However, there was a difference between the STZ groups and the control ($p = 0.015$) for left eye, and ($p = 0.019$) for the right eye, performed using the Chi square test. Below is the frequency distribution represented in figure 4.

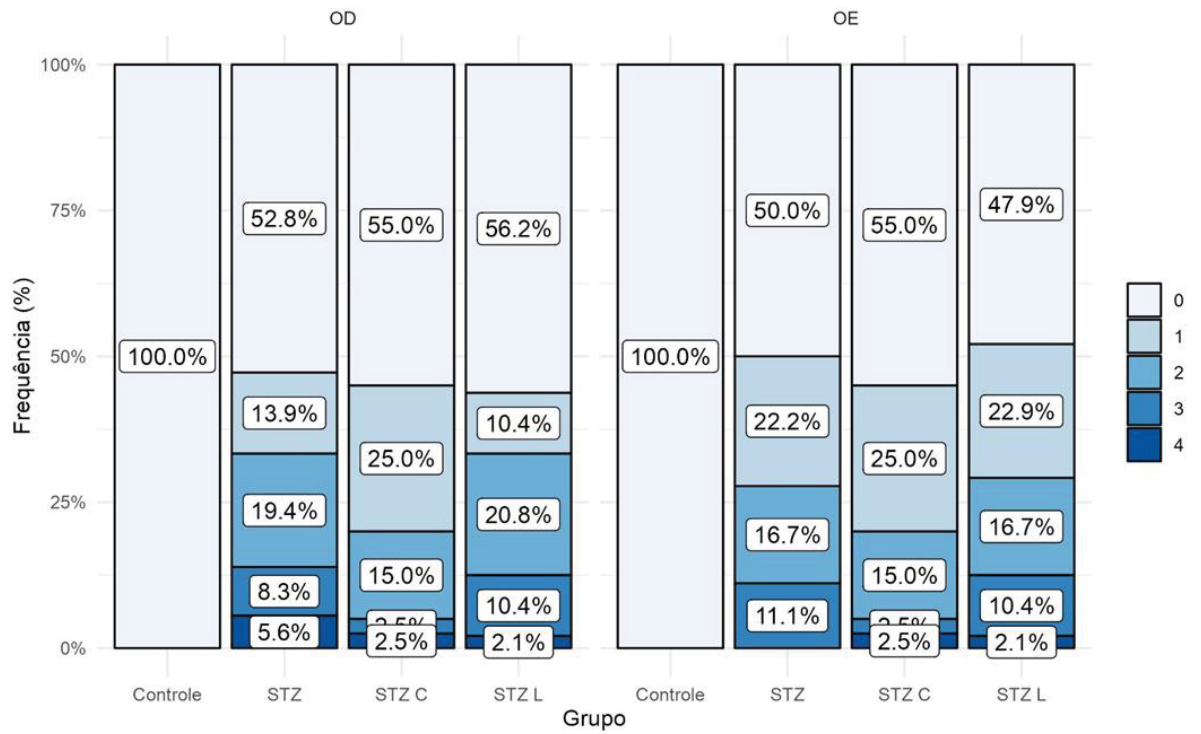


Figure 4. Bar graph of the rats evaluated in the right and left eye according to the groups for all time points. Note difference between the STZ groups and the control.

Representative images of each grade are illustrated in the figure 5.

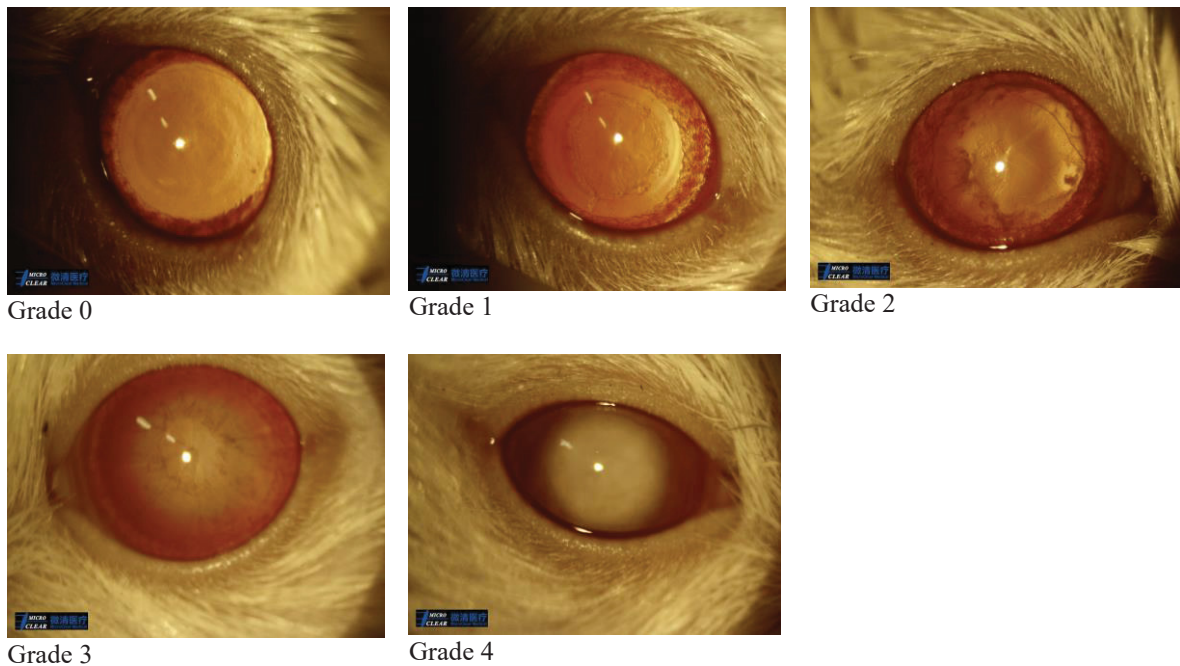


Figure 5. Representative images of each grade of cataract evaluation via slit lamp grades in rats

3.4.1.2 BODY WEIGHT AND BLOOD GLUCOSE

Over the weeks a significant difference was observed between the groups, $p < 0.0001$, represented in the figure 6.

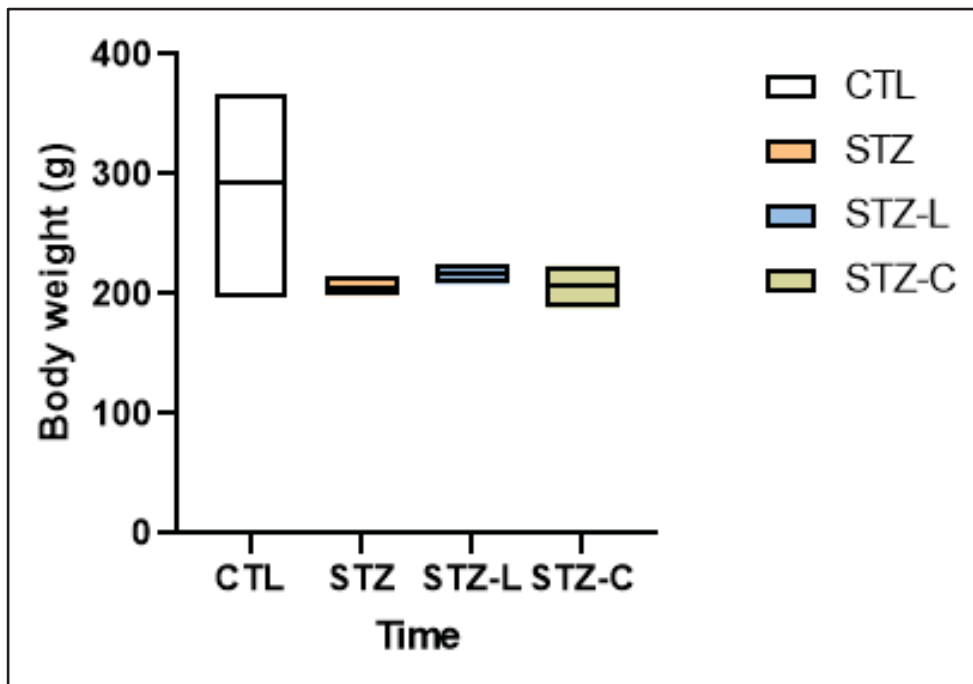


Figure 6. Box plot graph representing weight in the different groups of rats.

Still, the difference in body condition could be observed between the groups represented on figure 7.

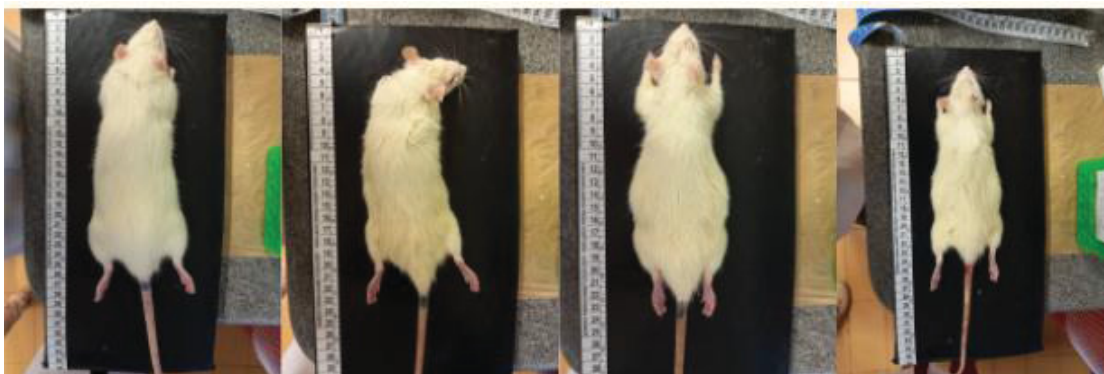


Figure 7. In the first image control group, and in the three subsequent images STZ groups. Showing lower body condition in the STZ groups.

In addition, over the weeks a significant difference was observed between the groups for blood glucose, obtaining a p value of $p < 0.0001$, represented in the figure 8. Difference was observed between all STZ treated groups and CTL group.

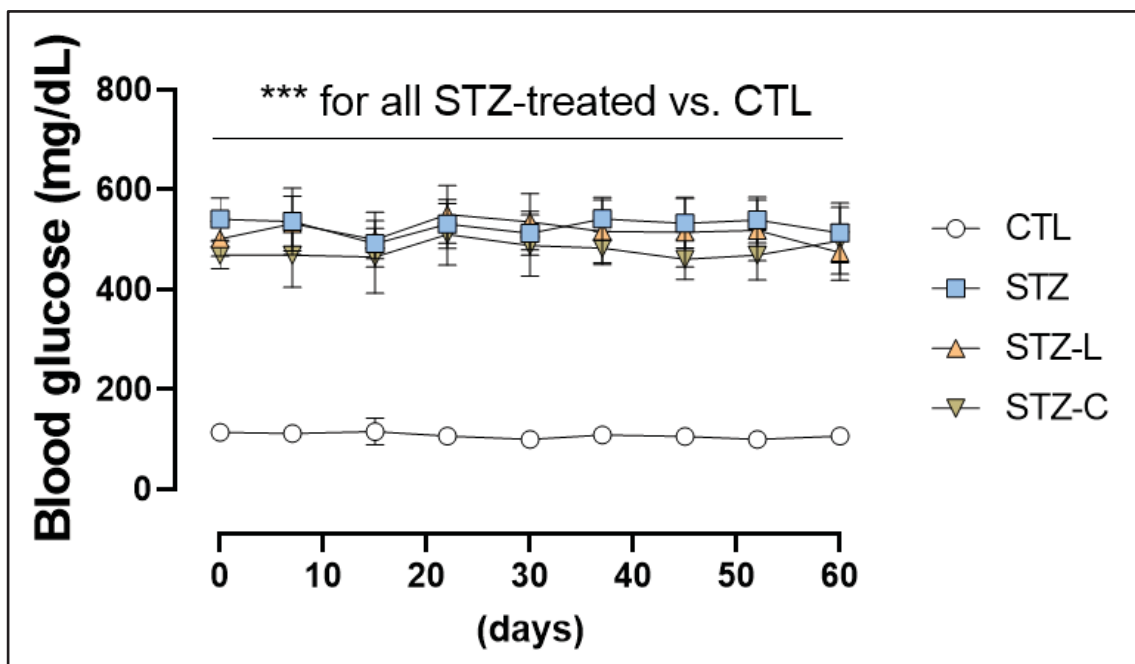


Figure 8. Blood glucose analyzed through 60 days.

3.4.1.3. ALT, AST, BLOOD KETONE BODIES, TG PLASMATIC, HEPATIC TG ANALYSIS

Of the biochemical parameters analyzed, ALT, AST, and blood ketone bodies, no significant difference was observed between the groups in any of the parameters, represented in figure 9.

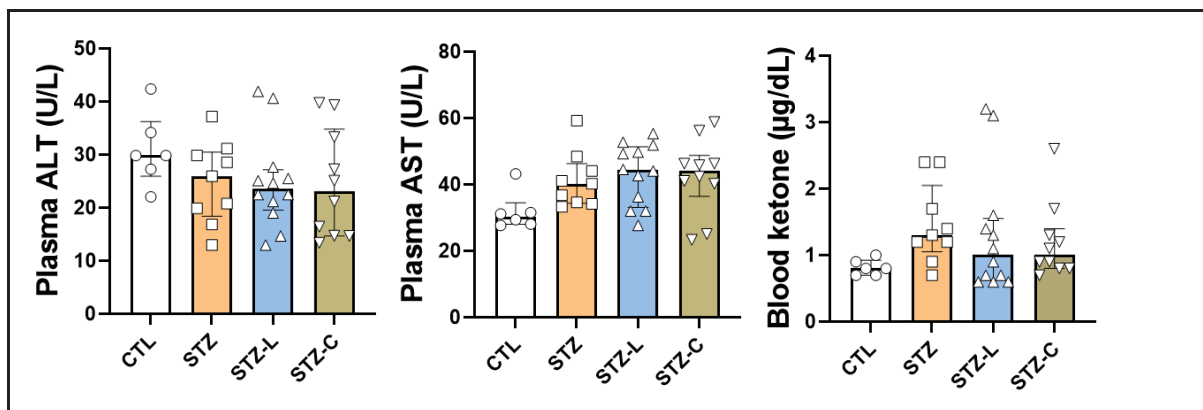


Figure 9. ALT, AST, and blood ketone bodies biochemical parameters analyzed

Mean for ALT, were 30.92 in control group, 24.80 in STZ group, 24.53 in STZ-L group and 24.52 in STZ-C group, and the standard deviation were 6.83 in control group, 7.72 in STZ group, 8.80 in STZ-L group and 10.17 in STZ-C group.

Mean for AST, were 31.86 in control group, 41.33 in STZ group, 43.21 in STZ-L group and 42.56 in STZ-C group, and the standard deviation were 5.79 in control group, 8.38 in STZ group, 9.22 in STZ-L group and 11.41 in STZ-C group.

Mean for blood ketone bodies, were 0.81 in control group, 1.46 in STZ group, 1.31 in STZ-L group and 1.20 in STZ-C group, and the standard deviation were 0.11 in control group, 0.60 in STZ group, 0.92 in STZ-L group and 0.57 in STZ-C group.

Also, there were no significant differences between groups in TG plasmatic analysis, with p value of $p = 0.99$. Mean for the analysis of TG plasmatic, were 129.4 in control group, 164.3 in STZ group, 108.2 in STZ-L group and 146.3 in STZ-C group, and the standard deviation were 64.99 in control group, 77.01 in STZ group, 72.64 in STZ-L group and 67.81 in STZ-C group.

However, TG hepatic analysis, were significant difference between STZ and CTL group ($p = 0.0002$), between STZ-L and CTL ($p = 0.0042$) and between STZ-C and STZ ($p = 0.0375$). Mean for the analysis of hepatic TG, were 5.28 in control group, 1.15 in STZ group, 1.58 in STZ-L group and 2.60 in STZ-C group, and the standard deviation were 1.39 in control

group, 0.63 in STZ group, 0.62 in STZ-L group and 0.96 in STZ-C group. These differences are represented in figure 10.

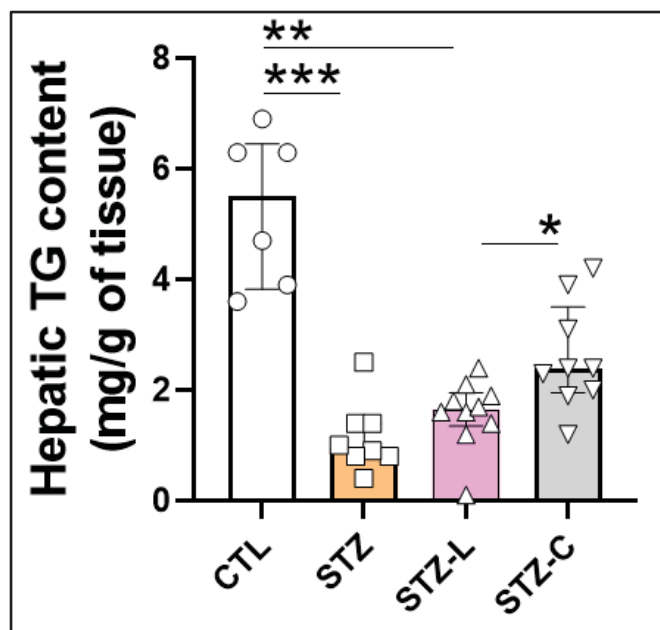


Figure10. Histogram demonstrating the hepatic TG content in the different groups. Observe significant difference between STZ and CTL group , and between STZ-C and STZ.

3.4.1.4. BODY FAT ANALYSIS (VISCERAL DEPOTS)

Epididymary fat analysis was a significant difference between the CTL and STZ groups with a $p = 0.004$. Mean for the analysis of epididymary fat, were 0.93 in control group, 0.25 in STZ group, 0.21 in STZ-L group and 0.25 in STZ-C group, and the standard deviation were 0.22 in control group, 0.02 in STZ group, 0.05 in STZ-L group and 0,07 in STZ-C group. These differences are represented on figure 11.

Omental fat analysis was a significant difference between the CTL and STZ-C groups ($p = 0.0002$). Mean for the analysis of omental fat, were 0.13 in control group, absent in STZ group, 0.02 in STZ-L group and 0.01 in STZ-C group, and the standard deviation were 0.03 in

control group, absent in STZ group, zero in STZ-L group and 0.006 in STZ-C group. These differences are represented on figure 11.

Retroperitoneal fat analysis was a significant difference between the groups ($p = 0.02$). Mean for the analysis of retroperitoneal fat, were 1.44 in control group, absent in STZ's groups, and the standard deviation were 0.54 in control group, absent in STZ's groups, These difference are represented on figure 11.

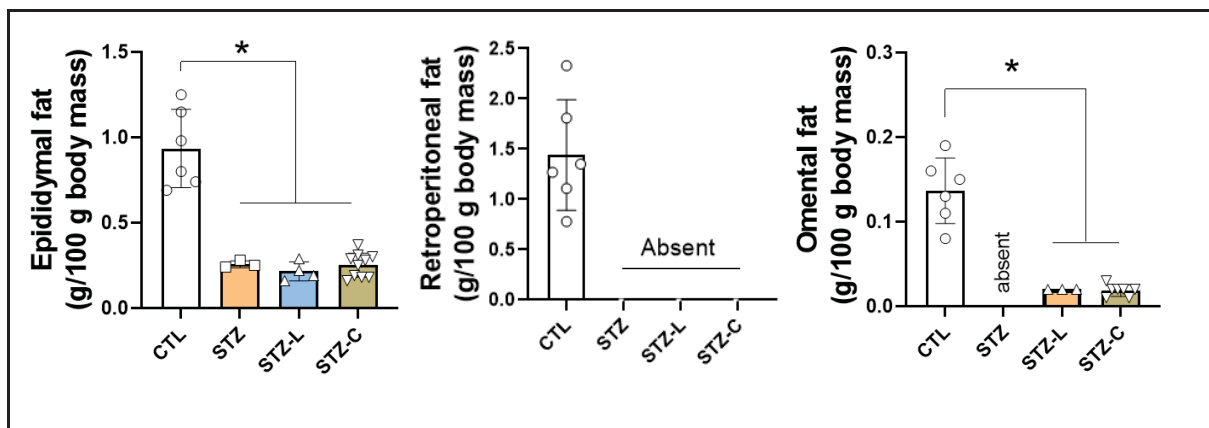


Figure 11. Histogram demonstrating body fat analysis. Epididymary fat analysis observe a significant difference between the CTL and STZ-L groups and between the CTL and STZ-C groups. Omental fat analysis was a significant difference between the CTL and STZ-C groups. Retroperitoneal fat analysis was a significant difference between the groups.

3.4.1.5. LENS HISTOPATHOLOGY

Histopathological analysis of the lens CTL and STZ-L groups were significantly different. The grades of cataract was higher in the STZ-L group ($p = 0.007$). These differences could be seen in both eyes among the groups, represented on figure 12 and 13.

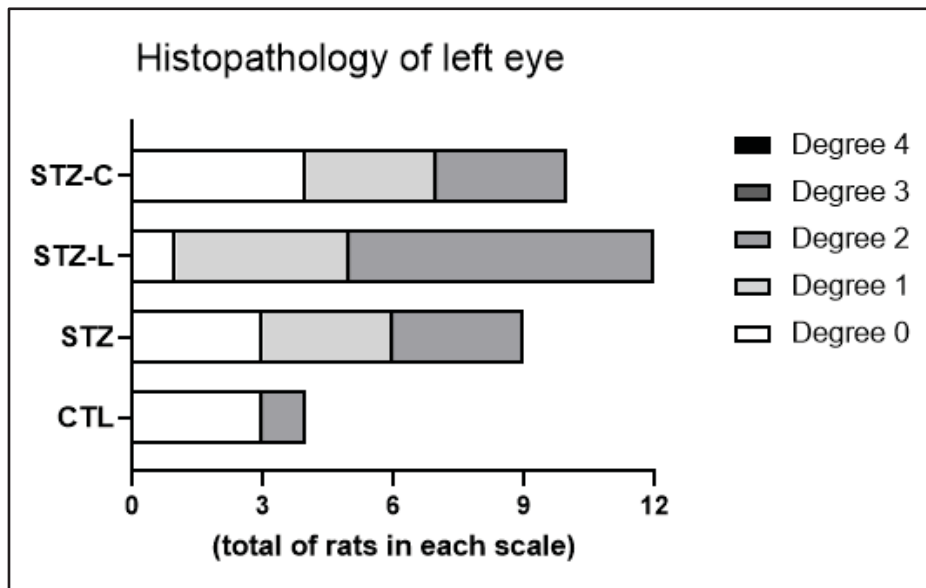


Figure 12. Histopathological analysis of the lens, on the left eye demonstrating that CTL and STZ-L groups are significantly different.

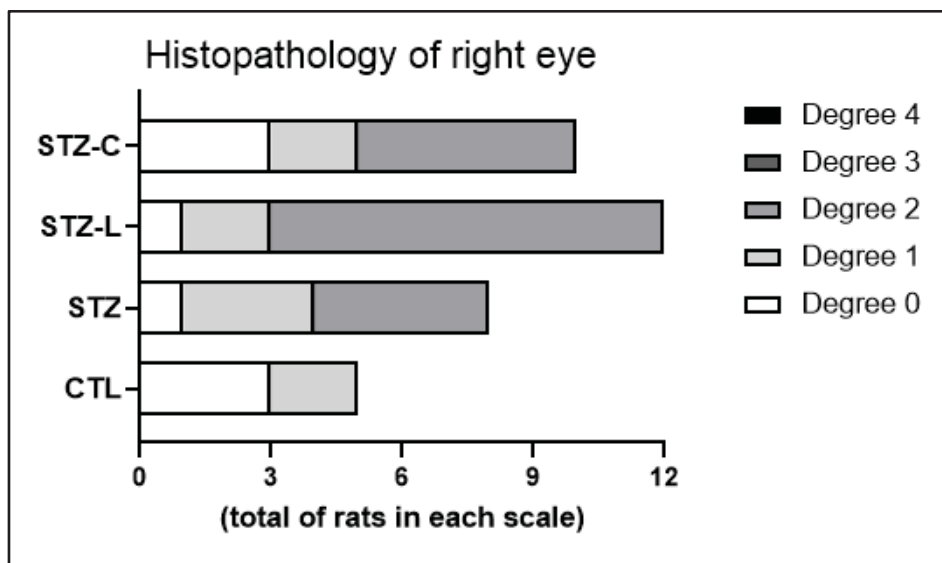


Figure 13. Histopathological analysis of the lens, on the right eye demonstrating that CTL and STZ-L groups are significantly different

The zero, one and two grade samples are represented in figures 14, 15 and 16. No samples were identified in grades 3 or 4.

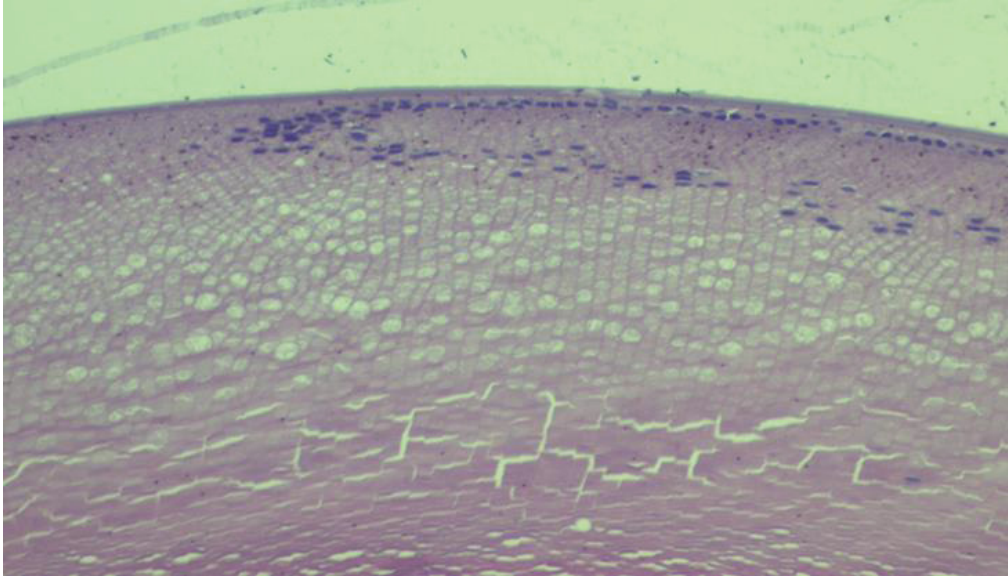


Figure 14. Note grade zero, presence of anterior epithelium with lens fibers.

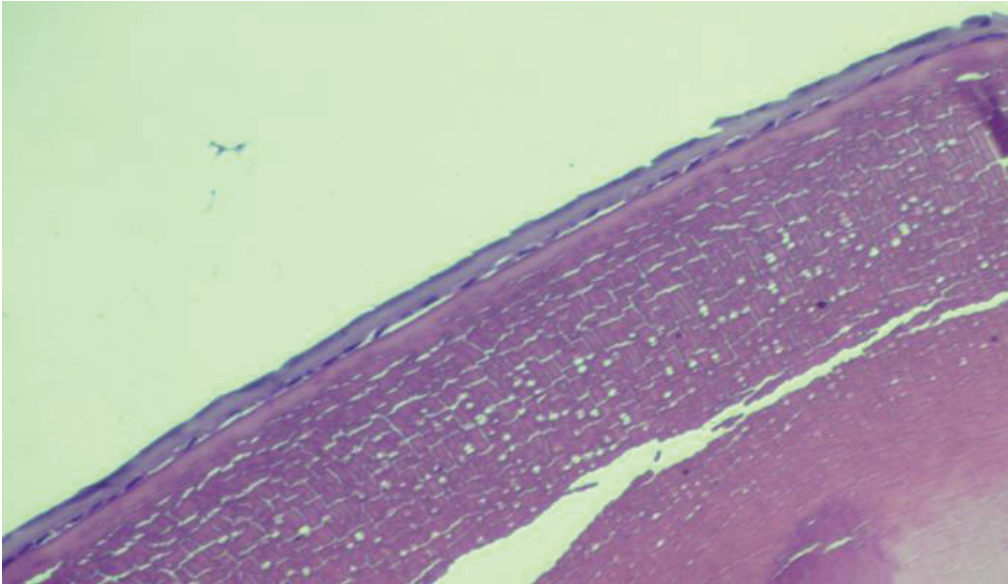


Figure 15. Note grade one, presence of anterior epithelium, lens fibers and vacuoles.

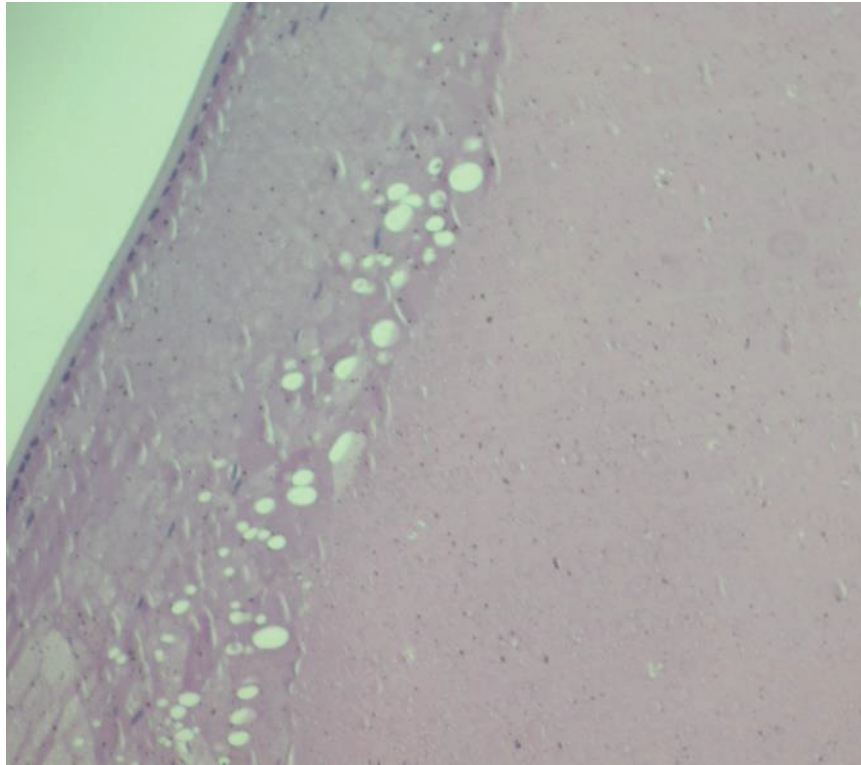


Figure 16. Note grade two, presence of anterior epithelium, lens fibers, vacuoles, and homogeneous area.

3.4.1.6. HISTOPATHOLOGY OF PANCREAS

STZ induced diabetes resulted in degenerative and lytic changes in the islets of langerhans of pancreas. The area of the pancreatic islets were not measured. Represented in Figure 17.

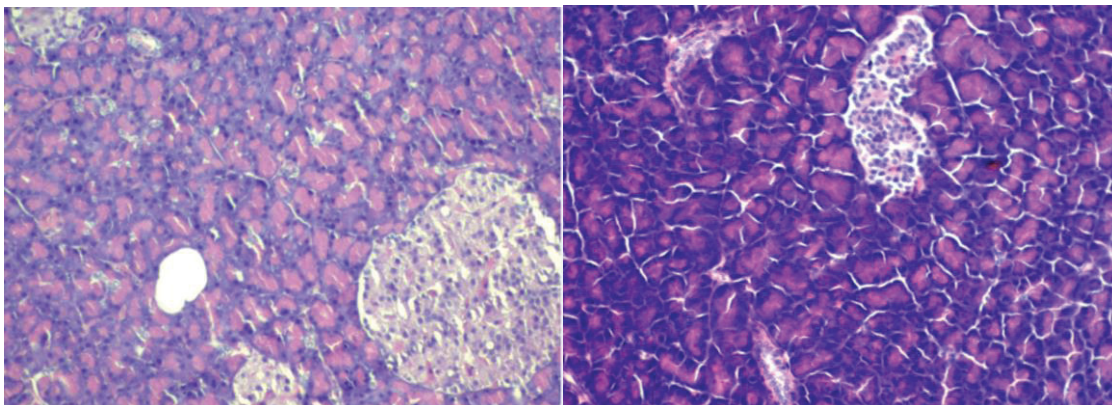


Figure 17. Photomicrograph of a tissue of the pancreas of the control group on the left and on de right pancreas of the STZ group. Hematoxylin and eosin staining. Magnification 10X. Dimension of the islet was also

considerably reduced and shrunken, on control group.

3.4.2. RESULTS IN DOGS

3.4.2.1. IOP MEASURE

IOP values was no significant difference was observed between groups and among time, presented on figure 18.

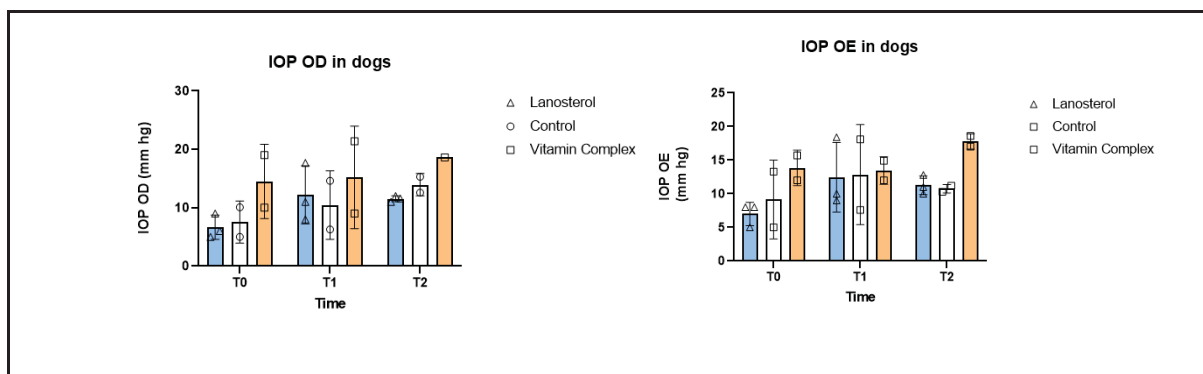


Figure 18. IOP values was no significant difference was observed between groups and among time

3.4.2.2. EVALUATION OF CATARACTS GRADES VIA SLIT LAMP

Once grades of groups were different from the beginning, we chose to make the comparison between the groups themselves through the times. Reprerented in the table and Table 2, Figures 19, with significant difference within lanosterol group, p value highlighted in the table for the lanosterol group, worsening cataracts grade.

Variable	Moment	Control				Vitamin complex				Lanosterol				p-value between groups *
		M	M D	SD	IIQ	M	M D	SD	IIQ	M	MD	SD	IIQ	
Right eye	T0	4	4	0	0	1	1	0	0	1,5	1,5	1,29	1,5	0,112
	T1	4,5	4,5	0,71	0,5	1	1	0	0	2,5	2	1,91	2,5	0,175
	T2	4,5	4,5	0,71	0,5	2,5	2,5	2,12	1,5	3	3	1,63	1	0,382
p-value between moments **		0,368				0,368				0,097				
Left Eye	T0	3,5	3,5	0,71	0,5	1	1	0	0	0,75	1	0,5	0,25	0,067
	T1	4,5	4,5	0,71	0,5	1	1	0	0	2,25	2	1,5	2,25	0,103
	T2	4	4	1,41	1	2,5	2,5	2,12	1,5	2,75	3	1,26	0,75	0,584
p-value between moments **		0,223				0,368				0,039				

*Kruskall-Wallis test ** Friedman Test

Table 2. Descriptive and inferential analysis of the degree of cataract of the dogs evaluated in the right and left eye in relation to all groups and time points. Note mean between each group.

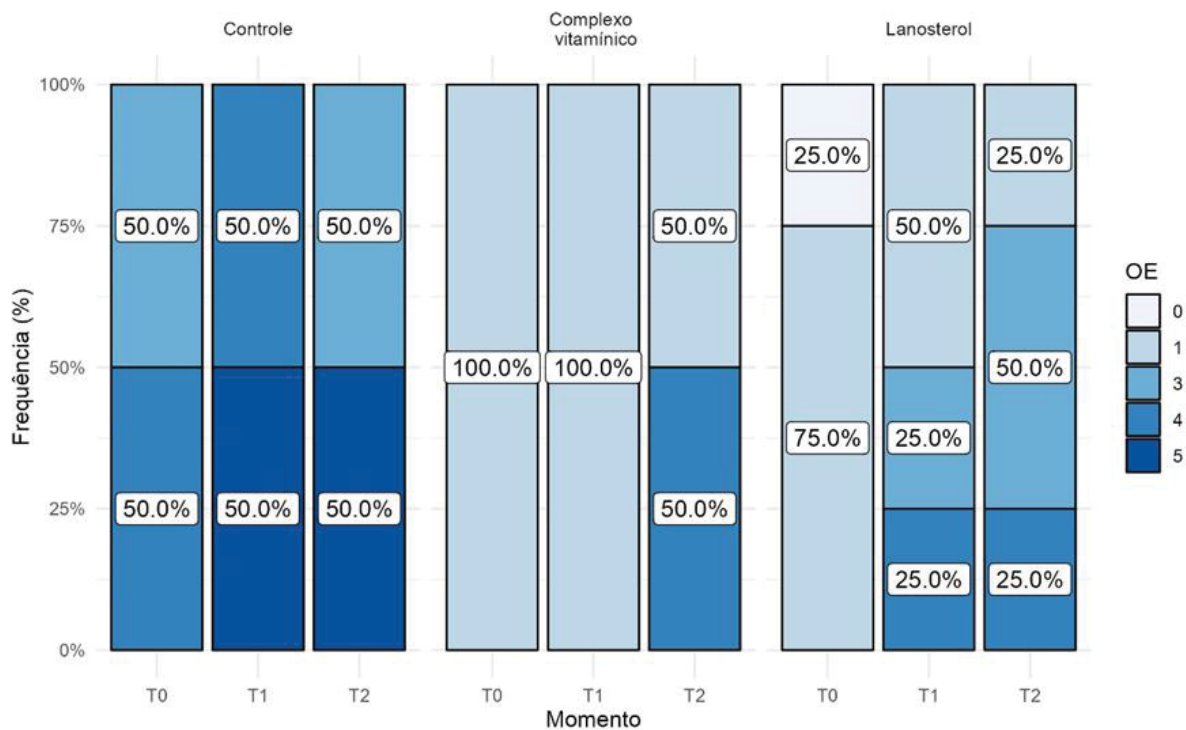
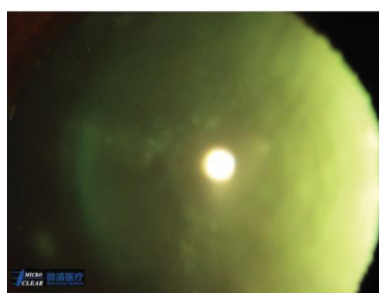
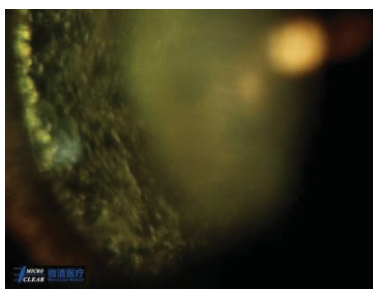


Figure 19. Descriptive analysis of the degree of cataract of the dogs evaluated in the left eye in relation to all groups and time points. Note significant difference within the lanosterol group.

Representative images of each grade are illustrated in the figure 20.



Grade 0



Grade 1



Grade 2



Figure 20. Representative images of each grade of cataract evaluation via slit lamp grades in dogs

3.4.2.3. EVALUATION OF ULTRASONOGRAPHIC MEASURES

Regarding ultrasonography values, there was a significant difference between anterior chamber (CA) measurements between the control and treated groups, with smaller values in the control compared to the treated ones. In both horizontal (AH) and vertical axial (AV) sections. $p=0.036$ on the right eye and $p=0.002$ on the left eye, between CTL and anti oxidant vitamin complex group. Represented in the figure 21 and 22.

The globe and lens measurements had no significant difference between the groups and times.

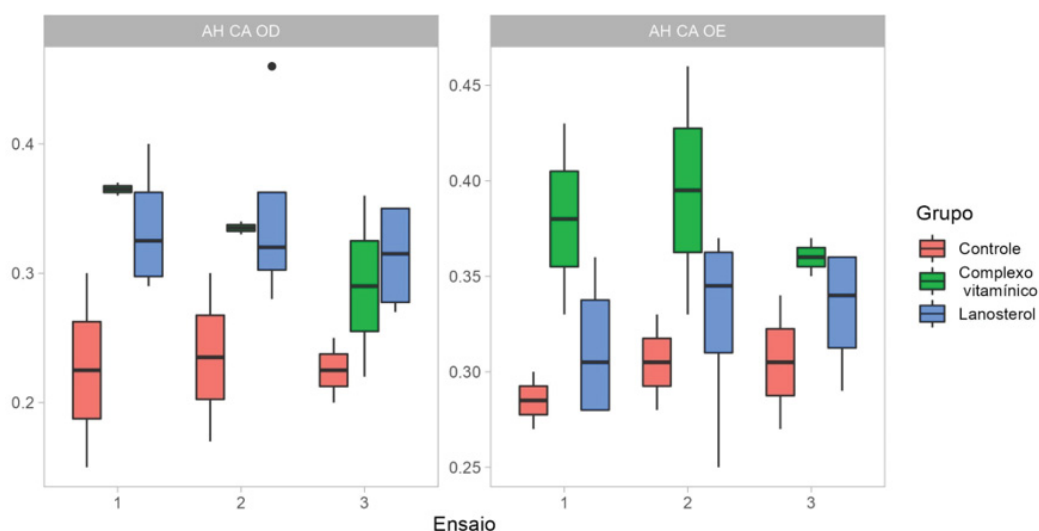


Figure 21. Boxplot of the dogs for the AH CA variable evaluated in the right and left eye in all trials and groups. Observe significant difference between anterior chamber (CA) measurements between the control and treated groups.

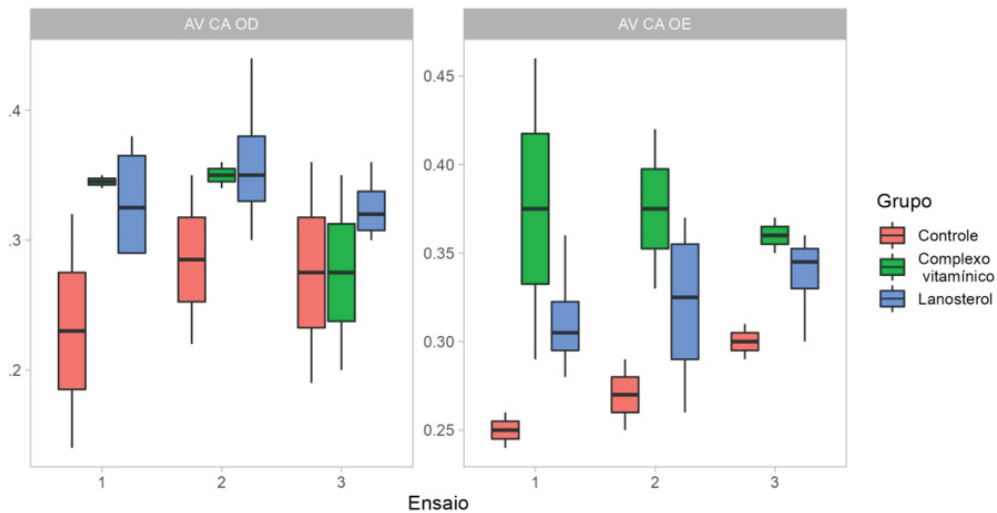


Figure 22. Boxplot of the dogs for the AV CA variable evaluated in the right and left eye in all trials and groups. Observe significant difference between anterior chamber (CA) measurements between the control and treated groups.

3.5.DISCUSSION

Hyperglycemia, increased thirst (polydipsia), hyperurination (polyuria), and glucose excretion (glycosuria), unexplained weight loss, gastric dysfunction, are common signs or symptoms of diabetes in humans that are observed in rats as well (Wang-Fischer *et al*, 2018, Furman, 2015, Goyal *et al*, 2016). These signs also could be seen in our study.

Still, the body weight in control rats increased with age as expected. Diabetic rats showed less body weight gain than sham animals. Polyuria was subjectively observed since the cages of the diabetic rats required bedding changes every day compared to weekly bedding changes required for the cages of control rats (Wang-Fischer *et al*, 2018). Also, alpha-lipoic acid (present in vitamin complex), had no effect on body weight, which concurred with previous study with STZ model as well (Lin *et al*, 2006).

Also, our choice of male rats instead of female rats corroborates with Kolb *et al* (1987), according to whom male pancreatic islet β -cells are more prone than female to STZ-induced cytotoxicity, male subjects are more popular for study (Kolb, 1987).

STZ induced diabetes resulted in degenerative and lytic changes in the islets of langerhans of pancreas. The lobules of pancreatic acini were seen with areas of fibrosis. There was depletion of β -cells and the dimension of the islet was also considerably reduced and shrunken (Anwerr *et al* 2007). Similar to what was observed in the rats of the STZ group.

In the second time of evaluation, twenty days after induction, five STZ rats already presented cataracts. Which were different from observed previous when cataracts were observed as early as 9 weeks after a STZ injection (Wang-Fischer *et al*, 2018). A possible explanation for this is the use of equipment for this precise evaluation, the slit lamp in our study. Since in another study evaluated with a slit lamp, this change could be noticed earlier, where the lens opacity in control rats also developed cataract during 6–10-week period (Thiraphathanavong *et al*, 2014). In addition, this may possibly influence the precision of grading scores, which reflect the real severity of cataract. To obtain the precise severity of cataract, the slit lamp examination should be performed while the pupil was dilated (Thiraphathanavong *et al*, 2014). Our study concurred with this fact, using a slit lamp and performing the examination with a dilated pupil.

Lanosterol had no effect on influencing the further progression of protein aggregate development because all lens opacities progressed to the advanced nuclear stage. Lens organ culture results strongly suggest that there was no apparent interaction between lanosterol and the experimentally aggregated lens proteins. Lanosterol or the presumably more potent 25-hydroxycholesterol both failed to interact with aggregated proteins in human lenses to increase the levels of soluble proteins by decreasing the levels of insoluble proteins (Daszynski *et al*, 2019). Cataract slit lamp grade findings showed no significant difference for rats, however slit

lamp grade for dogs and in the histopathology of rats showed worsening in the groups with lanosterol use. However, for dogs and in the histopathology of rats showed worsening in the groups with lanosterol use. Our findings also agree with Shanmugam *et al*, (2020) whereby twenty-five mM lanosterol solution failed to reverse nuclear opacity of human cataractous nuclei after 6 days of incubation (Shanmugam *et al*, (2015).

Still, additional protein-ligand interaction disclosed the underlying cause for the poor binding of oxysterols, such as lanosterol, to the current α B-crystallins models (Daszynski *et al*, 2019). This study can be used as a basis for research with lanosterol as an eye drops in different concentrations. Our study used a single concentration of lanosterol 5 mg/ml, eye drops, because it is a commercially available vehicle and concentration.

Anti-oxidant vitamin complex improved the alterations in lipid metabolism and liver function caused by STZ (accumulation of triacylglycerol in the liver). There was a partial but significant prevention. This group managed to preserve some of its hepatic lipid substrate. In the other STZ groups, this was not possible given the catabolic state due to the absence of insulin (which also occurs in their STZ-C). Once, streptozotocin-dependent increases in hepatic triacylglycerol biosynthesis and serum triacylglycerol content are related to alterations in insulin levels since these changes in triacylglycerol metabolism are reversed by insulin administration (Woods *et al*, 1981).

Studies using lens specific over-expression of aldose reductase in mice indicated a definitive role of aldose reductase in sugar cataracts (Lee, 1995). However, the physiological levels of aldose reductase are higher in the lenses of rats as compared to mice, and these high levels of aldose reductase presumably makes rats more prone to diabetic cataractogenesis (Varma, 1974, Williams, 2017). However, in our findings the group treated with alpha lipoic acid had no significant difference between the groups.

Ocu-GLO Rx™ appears to prevent further cataract formation in diabetic dogs where early changes such as equatorial vacuoles or cortical spokes have occurred (Williams *et al*, 2015). Unlike the findings found here, there was no difference with the use of the anti-oxidant vitamin complex based on the Ocu-GLO Rx™ formula.

Little difference in cataract severity was observed between the untreated and orally Ocu-GLO-treated diabetic rats, while the topical Optixcare EH-treated rats primarily developed suture accentuation, which represents the initial stage of sugar cataract formation. However, the ingredients in Optixcare EH do not directly inhibit AR. This suggests that the differences seen between Optixcare EH and Ocu-GLO are due to the strength of the antioxidant activities in the lens (Kador *et al*, 2014). This may explain our findings, with no significant response to the oral anti-oxidant vitamin complex.

The bulb and lens ultrasonographic measurements did not show significant differences, however, this could be justified by the low variability of the data. This shows that this may not be a very accurate analysis for evaluating the progression of diabetic cataract degrees because they are very close values. In addition, the small sample may not have expressed the real analysis of the population. In a study performed by Williams *et al* (2004), quantified changes in axial lens thickness in dogs with immature, mature, and diabetic cataracts and documented increases in lens axial thickness characteristic of intumescent mature and diabetic cataractous lenses. Moreover, found decreased anterior chamber depth in eyes with mature diabetic cataract (Williams *et al*, 2004). This finding of decreased anterior chamber was also seen in this study.

We did not measure the area of the pancreatic islets, like previous study, whereby the area of the pancreatic islets was measured, and the β -cell and inflammatory cell density in each islet were counted under a 40x objective lens and normalized per unit islet area (Wang-Fisher

et al, 2018). However, visually this occurred homogeneously in the STZ groups compared to the control group.

3.6.CONCLUSIONS

There was no previous study comparing these two drugs, and Only a few studies with lanosterol eye drops. In addition, the investigators concluded that the present experimental procedure was adequate to induce diabetic cataract in rats. Regarding dogs, we suggest studies with larger samples. In our findings, neither lanosterol eye drops nor anti oxidant vitamin complex containing aldose reductase inhibitor (alpha lipoic acid) obtained significant action to prevent diabetic cataracts, not reducing the opacity of the lens in rats and dogs. Still, the anti oxidant vitamin complex improved the alterations in lipid metabolism and liver function caused by STZ.

3.7.REFERENCES

- Alimohammadi *et al*. (2013). Protective and antidiabetic effects of extract from *Nigella sativa* on blood glucose concentrations against streptozotocin (STZ)-induced diabetic in rats: an experimental study with histopathological evaluation. *Diagnostic Pathology*, 8:137
- Anwerr T., *et al*. (2007). Protective effect of bezafibrate on streptozotocin-induced oxidative stress and toxicity in rats. *Toxicology* 229, 165–172.
- Davidson M. G. and Nelms, S. (2013). R.Diseases of the Lens and Cataract Formation. In: *Veterinary Ophthalmology*. Wiley Blackwell: Iowa (USA), 2 (21), 1214.
- Daszynski, D. M. *et al*. (2019). Failure of Oxysterols Such as Lanosterol to Restore Lens Clarity from Cataracts, *Scientific reports*. 9:8459.
- Furman, B.L. (2015). Streptozotocin-Induced Diabetic Models in Mice and Rats. *Curr. Protoc. Pharmacol.* 70:5.47.1-5.47.20.
- Goyal, S. N. *et al* (2016) Challenges and issues with streptozotocin-induced diabetes e A clinically relevant animal model to understand the diabetes pathogenesis and evaluate therapeutics. *Chemico-Biological Interactions* 244, 49-63.

- Kador, P. K. *et al* (2014). Topical Nutraceutical Optixcare EH Ameliorates Experimental Ocular Oxidative Stress in Rats. *Journal of Ocular Pharmacology and Therapeutics*. 30 (7), 593-602.
- Kojima M. *et al* (2007). Efficacy of α -Lipoic Acid Against Diabetic Cataract in Rat. *Jpn J Ophthalmol*, 51, 10–13.
- Kolb, H. (1987). Mouse models of insulin dependent diabetes: Low-dose streptozocin-induced diabetes and nonobese diabetic (NOD) mice. *Diabetes Metab. Rev.* 3:751-778.
- Lee, A.Y., CHUNG, S.K., CHUNG, S.S. (1995). Demonstration that polyol accumulation is responsible for diabetic cataract by the use of transgenic mice expressing the aldose reductase gene in the lens, *Proc. Natl. Acad. Sci. U.S.A.* 92, 2780–2784.
- Lin, J. *et al* (2006). Effect of R-(+)- α -lipoic acid on experimental diabetic retinopathy. *Diabetologia* 49: 1089–1096.
- Shanmugam, P.M., Barigali A, Kadaskar J, Borgohain S, Mishra DK, Ramanjulu R, *et al.* (2015). Effect of lanosterol on human cataract nucleus. *Indian J Ophthalmol*. 63, 888-90.
- Thiraphatthanavong, P. *et al* (2014). The Combined Extract of Purple Waxy Corn and Ginger Prevents Cataractogenesis and Retinopathy in Streptozotocin-Diabetic Rats. *Oxidative Medicine and Cellular Longevity*, 2014, 1-11.
- Varma S.D., Kinoshita, J H. (1974). The absence of cataracts in mice with congenital hyperglycemia, *Exp. Eye Res.* 19, 577–582.
- Zhao, L, *et al* (2015). Lanosterol reverses protein aggregation in cataracts. *Nature*, 523, 610.
- Wang-Fisher, Y e Garyantes, T. (2018). Improving the Reliability and Utility of Streptozotocin-Induced Rat Diabetic Model. *Journal of Diabetes Research.*, 2018, 1-14.
- Williams, D. (2004). Lens morphometry determined by B-mode ultrasonography of the normal and cataractous canine lens. *Veterinary Ophthalmology*. 7 (2), 91–95.
- Williams, D; Fitchie, A; Colitz, C. (2015). An Oral Antioxidant Formulation Delaying and Potentially Reversing Canine Diabetic Cataract: A Placebo-controlled Doublemasked Pilot Study. *Int J Diabetes Clin Res*, 2(1), 2-5.
- Williams, D, L. (2017). Effect of Oral Alpha Lipoic Acid in Preventing the Genesis of Canine Diabetic Cataract: A Preliminary Study. *Vet. Sci.* 4 (18), 1-6.
- Woods, J. A., *et al.* (1981). The Acute Effects of Streptozotocin-Induced Diabetes on Rat Liver Glycerolipid Biosynthesis. *Biochimica et Biophysica Acta*, 666, 482-492.

4. FINAL CONSIDERATIONS

Tonometry is an important resource in the early detection of glaucoma. Precision in resources for this purpose is necessary for prevention and treatment of glaucoma, especially in its early stages. The search for technological improvements in this equipment adds to the quality of its function. Findings of differences using Tono-Vera Vet® tonometer and Digital tonometer TD 8000® in rats, concluding that Tono-Vera Vet® measurements were superior to those of the TD 8000®, may contribute for quality improvement of this equipment.

In this sense, in the search for improvement and alternatives for diagnosis and treatment, investigating different therapies for diseases such as diabetic cataract brings benefits to health sciences. In our findings, neither lanosterol eye drops nor vitamin complex containing aldose reductase inhibitor (alpha lipoic acid) obtained preventive action for diabetic cataracts. However, other approaches can be taken such as investigating this outcome in females, in the case of mice. Investigating the action of lanosterol eye drops in different concentrations and for a longer period of time, could bring differentiated information and outcomes.

5. REFERENCES

- Alimohammadi *et al.* (2013). Protective and antidiabetic effects of extract from *Nigella sativa* on blood glucose concentrations against streptozotocin (STZ)-induced diabetic in rats: an experimental study with histopathological evaluation. *Diagnostic Pathology*, 8:137
- Anwerr T., *et al.* (2007). Protective effect of bezafibrate on streptozotocin-induced oxidative stress and toxicity in rats. *Toxicology* 229, 165–172.
- Davidson M. G. and Nelms, S. (2013). R.Diseases of the Lens and Cataract Formation. In: *Veterinary Ophthalmology*. Wiley Blackwell: Iowa (USA), 2 (21), 1214.
- Daszynski, D. M. *et al.* (2019). Failure of Oxysterols Such as Lanosterol to Restore Lens Clarity from Cataracts, *Scientific reports*. 9:8459.
- Ding, C., Wang, P., & Tian, N. (2011). Effect of general anesthetics on IOP in elevated IOP mouse model. *Experimental Eye Research*, 92(6), 512–520.
- Featherstone, H. J. and Heinrich, C. L. (2013). Ophthalmic Examination and Diagnostics Part 1: The Eye Examination and Diagnostic Procedures. In: *Veterinary Ophthalmology*. Kirk N. Gelatt. Wiley Blackwell, 1(10), 583-590.
- Furman, B.L. (2015). Streptozotocin-Induced Diabetic Models in Mice and Rats. *Curr. Protoc. Pharmacol.* 70:5.47.1-5.47.20.
- Goldblum, D., Kontiola, A. I., Mittag, T., Chen, B., & Danias, J. (2002). Non-invasive determination of intraocular pressure in the rat eye. Comparison of an electronic tonometer (TonoPen), and a rebound (impact probe) tonometer. *Graefe's Archive for Clinical and Experimental Ophthalmology*, 240 (11), 942–946.
- Gloe, S., Rothering, A., Kiland, J. A., & McLellan, G. J. (2019). Validation of the Icare® TONOVET plus rebound tonometer in normal rabbit eyes. *Experimental Eye Research*, 185.
- Goyal, S. N. *et al* (2016) Challenges and issues with streptozotocin-induced diabetes e A clinically relevant animal model to understand the diabetes pathogenesis and evaluate therapeutics. *Chemico-Biological Interactions* 244, 49-63.
- Kador, P. K. *et al* (2014). Topical Nutraceutical Optixcare EH Ameliorates Experimental Ocular Oxidative Stress in Rats. *Journal of Ocular Pharmacology and Therapeutics*. 30 (7), 593-602.
- Kojima M. *et al* (2007). Efficacy of a-Lipoic Acid Against Diabetic Cataract in Rat. *Jpn J Ophthalmol*, 51, 10–13.
- Kolb, H. (1987). Mouse models of insulin dependent diabetes: Low-dose streptozocin-induced diabetes and nonobese diabetic (NOD) mice. *Diabetes Metab. Rev.* 3:751-778.
- Kontiola, A. I., Goldblum, D., Mittag, T., & Danias, J. (2001). The induction/impact tonometer: A new instrument to measure intraocular pressure in the rat. *Experimental Eye Research*, 73(6), 781–785.

- Lee, A.Y., CHUNG, S.K., CHUNG, S.S. (1995). Demonstration that polyol accumulation is responsible for diabetic cataract by the use of transgenic mice expressing the aldose reductase gene in the lens, *Proc. Natl. Acad. Sci. U.S.A.* 92, 2780–2784.
- Lin, J. *et al* (2006). Effect of R-(+)- α -lipoic acid on experimental diabetic retinopathy. *Diabetologia* 49: 1089–1096.
- Minella, A. L., Kiland, J. A., Gloe, S., & McLellan, G. J. (2021). Validation and comparison of four handheld tonometers in normal ex vivo canine eyes. *Veterinary Ophthalmology*, 24(S1), 162–170.
- Ohashi, M., Aihara, M., Saeki, T., & Araie, M. (2008). Efficacy of TonoLab in detecting physiological and pharmacological changes in rat intraocular pressure: Comparison of TonoPen and microneedle manometry. *Japanese Journal of Ophthalmology*, 52(5), 399–403.
- Pease, M. E., Hammond, J. C., & Quigley, H. A. (2006). *Manometric Calibration and Comparison of TonoLab and TonoPen Tonometers in Rats With Experimental Glaucoma and in Normal Mice*. 15 (6), 512-519.
- Pereira, F. Q., Bercht, B. S., Soares, M. G., da Mota, M. G. B., & Pigatto, J. A. T. (2011). Comparison of a rebound and an applanation tonometer for measuring intraocular pressure in normal rabbits. *Veterinary Ophthalmology*, 14(5), 321–326.
- Plummer, C. E., Reignier, A., Gelatt, K. N. The Canine Glaucomas. In: *Veterinary Ophthalmology*. Wiley-Blackwell, 2 (19), 1050.
- Rocha-Sousa, A., Pereira-Silva, P., Tavares-Silva, M., Azevedo-Pinto, S., Rodrigues-Araújo, J., Pinho, S., Avelino, A., Falcão-Reis, F., & Leite-Moreira, A. (2014). Identification of the ghrelin-GHSR 1 system and its influence in the modulation of induced ocular hypertension in rabbit and rat eyes. *Peptides*, 57, 59–66.
- Rodrigues, B. D., Montiani-Ferreira, F., Bortolini, M., Somma, A. T., Komáromy, A. M., & Dornbusch, P. T. (2021). Intraocular pressure measurements using the TONOVET® rebound tonometer: Influence of the probe-cornea distance. *Veterinary Ophthalmology*, 24(S1), 175–185.
- Shanmugam, P.M., Barigali A, Kadaskar J, Borgohain S, Mishra DK, Ramanjulu R, *et al*. (2015). Effect of lanosterol on human cataract nucleus. *Indian J Ophthalmol*. 63, 888-90.
- Sereno, M. G.; Cremonini, D. N.; Chiurchiu, J. L. V. (2021) Comparison Between Rebound Tonometer Tonovet® and TD8000® in normotensive dogs. In: *Archives of Veterinary Science*, XVII CBOV, 26, (4), 15-97.
- Snyder, K. C., Lewin, A. C., Mans, C., & McLellan, G. J. (2018). Tonometer validation and intraocular pressure reference values in the normal chinchilla (*Chinchilla lanigera*). *Veterinary Ophthalmology*, 21(1), 4–9.
- Stamper, R.L. History of intraocular pressure and its measurement. *Optom Vis Sci*. 2011;88(1):E16-E28.

Thiraphatthanavong, P. *et al* (2014). The Combined Extract of Purple Waxy Corn and Ginger Prevents Cataractogenesis and Retinopathy in Streptozotocin-Diabetic Rats. *Oxidative Medicine and Cellular Longevity*, 2014, 1-11.

Varma S.D., Kinoshita, J H. (1974). The absence of cataracts in mice with congenital hyperglycemia, *Exp. Eye Res.* 19, 577–582.

Zhao, L, *et al* (2015). Lanosterol reverses protein aggregation in cataracts. *Nature*, 523, 610.

Wang-Fisher, Y e Garyantes, T. (2018). Improving the Reliability and Utility of Streptozotocin-Induced Rat Diabetic Model. *Journal of Diabetes Research.*, 2018, 1-14.

Wang, X., Dong, J., & Wu, Q. (2013). Twenty-four-hour measurement of IOP in rabbits using rebound tonometer. *Veterinary Ophthalmology*, 16(6), 423–428.

Weinreb, R.N.; Khaw, P. T. (2004). Primary open-angle glaucoma. *Lancet.*;363(9422):1711-1720.

Williams, D. (2004). Lens morphometry determined by B-mode ultrasonography of the normal and cataractous canine lens. *Veterinary Ophthalmology*. 7 (2), 91–95.

Williams, D. L. (2012). Common features of exotic animal ophthalmology. In: *Ophthalmology of exotic pets*. Wiley-Blackwell, 2 (7), 86-106.

Williams, D; Fitchie, A; Colitz, C. (2015). An Oral Antioxidant Formulation Delaying and Potentially Reversing Canine Diabetic Cataract: A Placebo-controlled Doublemasked Pilot Study. *Int J Diabetes Clin Res*, 2(1), 2-5.

Williams, D, L. (2017). Effect of Oral Alpha Lipoic Acid in Preventing the Genesis of Canine Diabetic Cataract: A Preliminary Study. *Vet. Sci.* 4 (18), 1-6.

Woods, J. A., *et al.* (1981). The Acute Effects of Streptozotocin-Induced Diabetes on Rat Liver Glycerolipid Biosynthesis. *Biochimica et Biophysica Acta*, 666, 482-492.

APPENDIX



**UNIVERSIDADE FEDERAL DO PARANÁ
SETOR DE CIÊNCIAS AGRÁRIAS
COMISSÃO DE ÉTICA NO USO DE ANIMAIS**

CERTIFICADO

Certificamos que o protocolo número 034/2021, referente ao projeto de pesquisa “Uso de lanosterol colírio e medicação via oral complexo inibidor AR para prevenção de catarata diabética em cães – estudo comparativo e de eficácia”, sob a responsabilidade de **Fabiano Montiani Ferreira** – que envolve a produção, manutenção e/ou utilização de animais pertencentes ao filo Chordata, subfilo Vertebrata (exceto o homem), para fins de pesquisa científica ou ensino – encontra-se de acordo com os preceitos da Lei nº 11.794, de 8 de Outubro de 2008, do Decreto nº 6.899, de 15 de julho de 2009, e com as normas editadas pelo Conselho Nacional de Controle da Experimentação Animal (CONCEA), e foi aprovado pela COMISSÃO DE ÉTICA NO USO DE ANIMAIS (CEUA) DO SETOR DE CIÊNCIAS AGRÁRIAS DA UNIVERSIDADE FEDERAL DO PARANÁ - BRASIL, com grau 1 de invasividade, em 03/09/2021.

Finalidade	Pesquisa
Vigência da autorização	Julho/2021 até Março/2022
Espécie/Linhagem	<i>Canis lupus familiaris (canino)</i>
Número de animais	12
Peso/Idade	1kg-15kg/2 a 12 anos
Sexo	Macho e fêmea
Origem	Clinicas veterinárias particulares de Florianópolis, Santa Catarina, Brasil.

*A autorização para início da pesquisa se torna válida a partir da data de emissão deste certificado.


CERTIFICATE

We certify that the protocol number 034/2021, regarding the research project “The use of lanosterol eye drops and oral medication ar inhibitor complex for the prevention of diabetic cataract in dogs – a comparative and efficacy study” under **Fabiano Montiani Ferreira** – which includes the production, maintenance and/or utilization of animals from Chordata phylum, Vertebrata subphylum (except Humans), for scientific or teaching purposes – is in accordance with the precepts of Law nº 11.794, of 8 October 2008, of Decree nº 6.899, of 15 July 2009, and with the edited rules from Conselho Nacional de Controle da Experimentação Animal (CONCEA), and it was approved by the ANIMAL USE ETHICS COMMITTEE OF THE AGRICULTURAL SCIENCES CAMPUS OF THE UNIVERSIDADE FEDERAL DO PARANÁ (Federal University of Paraná, Brazil), with degree 1 of invasiveness, on 2021, September 3rd.

Purpose	Research
Validity	July/2021 until March/2022
Species/Line	<i>Dogs (Canis familiaris)</i>
Number of animals	12
Weight/Age	From 1kg to 15kg/ from 2 to 12 years old
Sex	Male and female
Origin	Private veterinary clinics in Florianópolis, Santa Catarina, Brazil.

*The authorization to start the research becomes valid from the date of issue of this certificate.

Curitiba, 03 de setembro de 2021


Alex Maiorka
Coordenador
Comissão de Ética no Uso de Animais
AG - UFPR



CERTIFICADO

Certificamos que a proposta intitulada "Uso de lanosterol colírio e medicação via oral ocu-glo® para prevenção de catarata diabética em ratos □ estudo comparativo e de eficácia", protocolada sob o CEUA nº 8045041220 (ID 001798), sob a responsabilidade de **Alex Rafacho** e equipe; *Lenara Gonçalves e Souza; Milena dos Santos Almeida* - que envolve a produção, manutenção e/ou utilização de animais pertencentes ao filo Chordata, subfilo Vertebrata (exceto o homem), para fins de pesquisa científica ou ensino - está de acordo com os preceitos da Lei 11.794 de 8 de outubro de 2008, com o Decreto 6.899 de 15 de julho de 2009, bem como com as normas editadas pelo Conselho Nacional de Controle da Experimentação Animal (CONCEA), e foi **aprovada** pela Comissão de Ética no Uso de Animais da Universidade Federal de Santa Catarina (CEUA/UFSC) na reunião de 16/04/2021.

We certify that the proposal "Use of lanosterol eye drops and ocu-glo® oral medication to prevent diabetic cataracts in rats - comparative and efficacy study", utilizing 64 Heterogenics rats (64 males), protocol number CEUA 8045041220 (ID 001798), under the responsibility of **Alex Rafacho** and team; *Lenara Gonçalves e Souza; Milena dos Santos Almeida* - which involves the production, maintenance and/or use of animals belonging to the phylum Chordata, subphylum Vertebrata (except human beings), for scientific research purposes or teaching - is in accordance with Law 11.794 of October 8, 2008, Decree 6899 of July 15, 2009, as well as with the rules issued by the National Council for Control of Animal Experimentation (CONCEA), and was **approved** by the Ethic Committee on Animal Use of the Federal University of Santa Catarina (CEUA/UFSC) in the meeting of 04/16/2021.

Finalidade da Proposta: **Pesquisa**

Vigência da Proposta: de **02/2021** a **07/2022**

Área: **Ciências Fisiológicas**

Origem: **Biotério Central**

Espécie: **Ratos heterogênicos**

sexo: **Machos**

idade: **8 a 10 semanas**

N: **64**

Linhagem: **Wistar**

Peso: **200 a 250 g**

Local do experimento: Os experimentos serão realizados no Laboratório de Investigação de Doenças Crônicas - LIDoC (www.lidoc.ccb.ufsc.br), do Departamento de Ciências Fisiológicas (Centro de Ciências Biológicas - CCB) da Universidade Federal de Santa Catarina, UFSC (Rua Roberto Sampalo Gonzaga s/n Trindade, Florianópolis/ SC).

Florianópolis, 16 de maio de 2022

Luciana Aparecida Honorato
Presidente da Comissão de Ética no Uso de Animais
Universidade Federal de Santa Catarina

Vanessa Rafaella Foletto da Silva
Vice-Presidente da Comissão de Ética no Uso de Animais
Universidade Federal de Santa Catarina